

Iridology Guide by Oliver

Shameless Plug:

If you read all this and think “I can’t be asked to do this myself” OR “I don’t understand this” OR “I don’t see the iris signs” OR you get the idea...

Then go to primal-diet.net/iris-reading to get iridology done by me!

Money goes into me affording food and then when I have enough income to quit my job and do this full-time, run large scale iridology testing to build a more concrete database, etc.

Contents

- 1. Constitution, Mapping, Areas, Iridology vs Palmistry*
- 2. Examples of different toxins/people with 1+ conditions*
- 3. Lots of Quotes Directly from Aajonus*
- 4. Palmistry*

NOTE: I am talking about the iridology of Aajonus Vonderplanitz, which differs slightly or significantly from other iridologists. So don’t go and claim it’s wrong if you have a different perspective and are assuming I mean Jensen, Pesek, Constitutional, Emotional/Trauma Iridology. When I say ‘in Iridology’, I mean Aajonus’ iridology.

NOTE 2: Where you see the symbol below, it means I have included that information speculatively - that information is possibly true but not for certain, often interpreted from more vague comments Aajonus made, especially without video to go with the audio, to see what he was seeing. I hope to reduce the uncertainty by taking on a high volume of people’s palms+irises+health histories.

Symbol: (?) OR I just explain that something is observational/needs more testing

“A: What I do is a short mini consult with the palms, and it's not [unintelligible]. It's not a psychic thing. It's like the Chinese patterns, colorations of mouths on the hands.

And that's \$40. It takes 6 to 10 minutes, and what I can do is I can tell how functional your glands are. I can see how your blood's doing, how your lymphatic system is doing, and I can suggest foods for you to basically focus on to, you know, make it easier for you to get on to the diet. You can come to me for my full consult. The initial consult is about 70 minutes, almost an hour and 15 minutes. And with that, I photograph the irises, and I blow them up. You can see a pinprick on the eye as big as my finger. So, you can see, I can see everything in the body that is extracellular, outside the cells. If it's inside the cells, I can't really tell easily. But in the palms, I can. Because that's mostly your intercellular activity. So, putting the two together gives me a complete in and outside picture of the body. And in that full consult, I'll go through every part of the body and show you what's there, tell you what's going on, why it's the problem, how you can remedy it. And then at the end, after I've seen everything, and you also have to mind the health history. And I don't look at it until I've finished the reading before I suggest what there is. There's only maybe one out of 200 that I've missed something. So that also verifies so that I know what I'm talking about, because I've already talked about your symptoms and problems before you told me. Okay? So you know what I'm talking about. Then I will tell you what to eat, what time to eat, how much to eat, all of that. To help you achieve better health quicker. And that's the story. Now, the 6 to 10 minutes, I usually invite everybody who wants to listen to learn more, to listen along with when I read people.”

1. Constitution, Mapping, Areas

Constitution

In Iridology, constitution shows 2 interconnected concepts:

- % of cells alive in an area
- How functional cells are in an area

Constitution is best described visually as how straight, thick, layered and tightly packed together iris fibers are.

Straight - When fibers are perfectly straight and unbroken from the nerve wreath to the iris edge it means that area is very strong

Thick - Similar to straight, thick fibers mean the cells in that area are functioning very well

Layered - If you can see black, even between straight fibers, rather than a slightly darker blue/amber depending on true eye colour, it means you have a lot of metals.

Tightly packed - Lack of gaps between fibers, often seen in conjunction with having straight fibers, indicates stronger areas in the body.

Here are several examples of good and bad constitution, both specific and non-specific to bodily areas. This section looks at the whole eye as an average, which Aajonus did when determining his own cellular life. The weaker the constitution, the less cells are alive and/or functioning well in the body. Broken, gapping constitution means you have lower cellular life, which takes a long time to heal, sped up first and foremost by raw meat consumed with adequate raw fat, sped up more by royal jelly, pate meat, and other methods individual to the person.

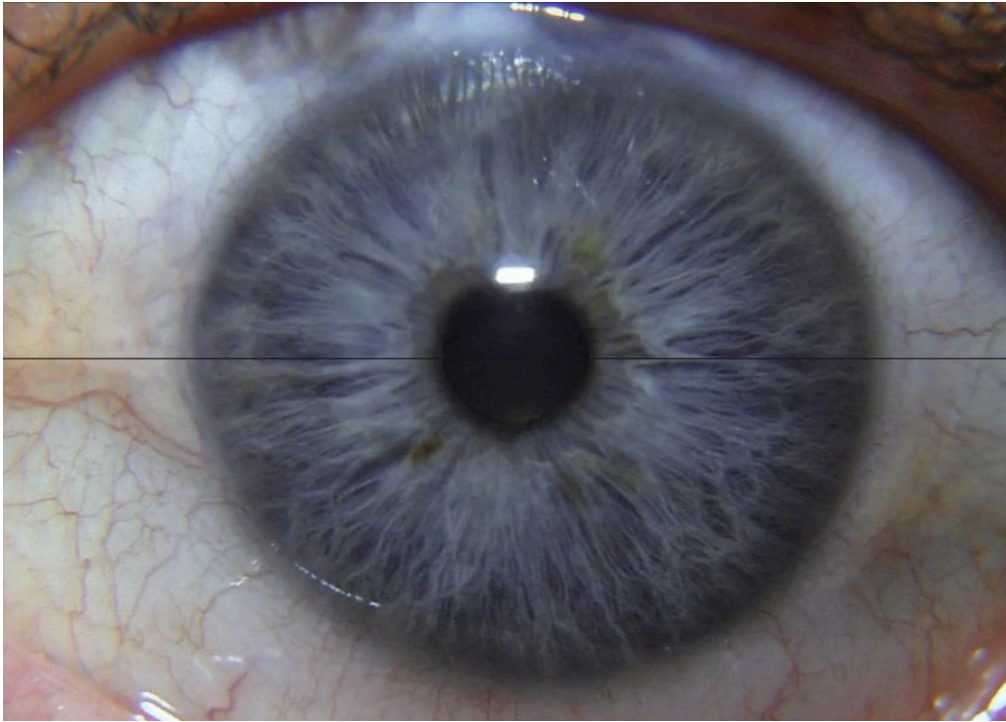
In many cases it is hard to tell the constitution in darker brown and especially in near-black eyes. Dark brown and near-black are not true eye colours. If you have eyes where nothing is visible due to brown or black overlay, gain weight and lose it over many months, do hot baths, cheese trains, and you will see much more colour and detail in the first few years. Extract from Aajonus on dark eyes lightning and revealing things (important bits in **bold**):

“A: Yes. Okay. What I've learned over the years is that the body will go through tremendous detoxes on its own that can be frightening and can be debilitating and worrisome and cause people to freak. So to avoid that, what I decided was I would experiment with different detox programs. And the ones that I found, the one that I found worked the best were people got flus and colds that didn't wipe them out. They can continue working and they still feel pretty good. And all they're doing is filling up a lot of handkerchiefs or towels with mucus. Or maybe just debilitated and having to sleep a lot more. That is to put on lots of fat for a cycle of three months. That means gaining anywhere from a normal weight, let's say what your normal weight is supposed to be for your size and your frame, you need to gain 15 to 35 pounds over that weight. And that means you get chubby. And what I found is that that fat goes in there and will absolutely start dissolving the compounds that make you ill, that have stored in your body, plaque, all kinds of things. Just like motor oil in your car will absorb the carbons and absorb the shavings from the piston movements and the rod movements. It will absorb all that, turn black, and then you change the oil. And that's what you do in the human body. **With my girlfriend, she didn't know why she went chronically fatigued at 20 years old and had been chronically fatigued for 7 years, almost 8 years when I met her. She was 28. Her eyes were dark brown, full of plaque and garbage. One sister had hazel eyes and the other sister had blue eyes. Her mother had dark brown eyes. Her father had very dark brown and green eyes. Both of her parents were very toxic. They raised these children on microwave food and McDonalds.** They didn't have anything else. Microwave food, TV dinners, stuff like that, microwave. Why she got so ill and her younger sisters didn't, probably because she ended up in the hospital with abdominal surgery in her

teens, early teens. She didn't know why she was chronically fatigued. She could only work one day a week for 8 years since she graduated from college. She didn't know what was going on. She didn't have a clue. **Well, I took a look in her eyes and I found worry circles. Worry circles indicate that wherever you hold tension you cannot store toxins.** That's usually a person who does well with exercise. **Hers were blue. That meant her eyes were blue. Really blue and her eyes were dark brown.** So I began with her doing this overweight thing and she was a skinny girl. And she was not my girlfriend when we started. She was a patient. Yes, and I went overboard. And it wasn't my suggestion, but this was after 6 months. And anyway, I got her... I convinced her that she needed to get fat. And she said, I'm skinny and beautiful. I'm ill, but I'm skinny and beautiful. And I said, I agree with that, but you're skinny and ugly.

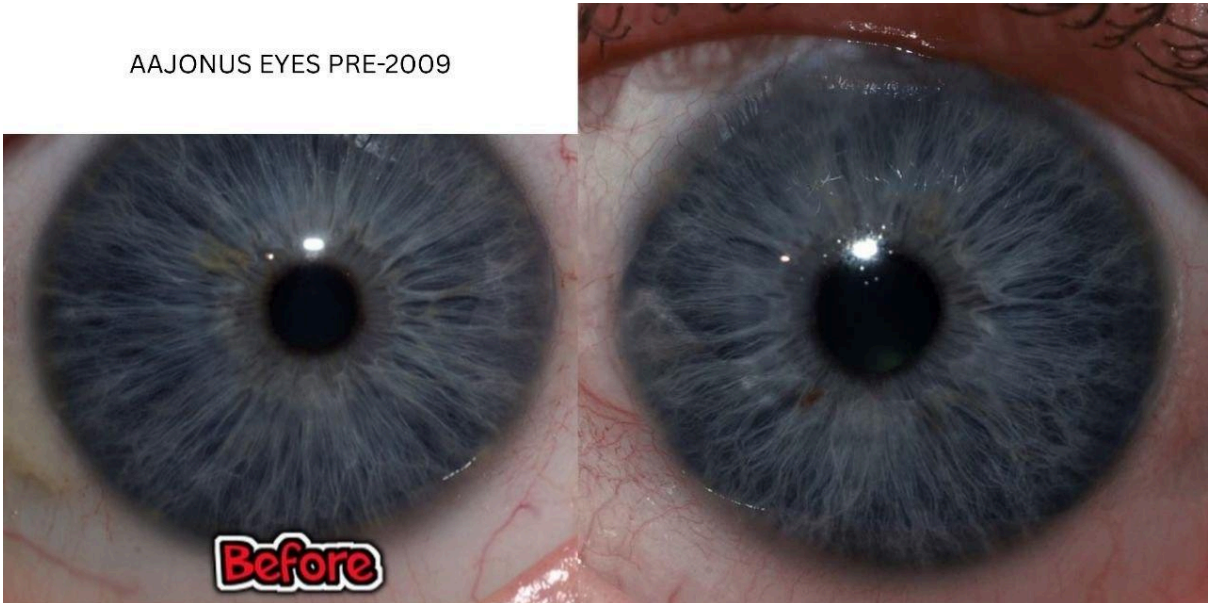
Because you are not healthy, how can you be beautiful? So I suggested that she get real fat. So she gained 35 pounds. She went from 112 pounds to 140 some pounds. And she did not look fat, she just looked stocky and heavy. She hated that word. She hated me to say stocky. I'm not stocky. I'm not stocky. It's the worst word you can use for a woman. I said, but that means to me you're strong looking. Don't say that to a woman. Don't say that to a woman. **But in one and a half years, I had never seen it before, her eyes went from dark brown to hazel. Now, when that cleaned out, all of a sudden I saw she had cancer of the kidney, attached to the adrenal gland, cancer of the breast, and a cancer in her hip. I only told her about the cancer in the kidney. She went and had a sonogram done, and sure enough, she had a tumor there.** Those tumors have not shrunk, have not changed. But all of the other chemicals in her body are dissolving and removing faster than I've seen anybody else, because she will... She'll go fat, and then she'll take off the weight, get fat, take off the weight, in a cycle, in a six-month cycle. Three months putting it on, three months taking it off. And I'm doing this with all my clients now. And they are moving much faster. They don't get the heavy flus. They don't get all the meningitis. They don't get all of those other, you know, pneumonia, everything that most people need to go through.”

Aajonus' reduction in scar tissue (good) from 2005 to 2007, and reduction in cellular life/increase in scar tissue (bad) after forced injections:

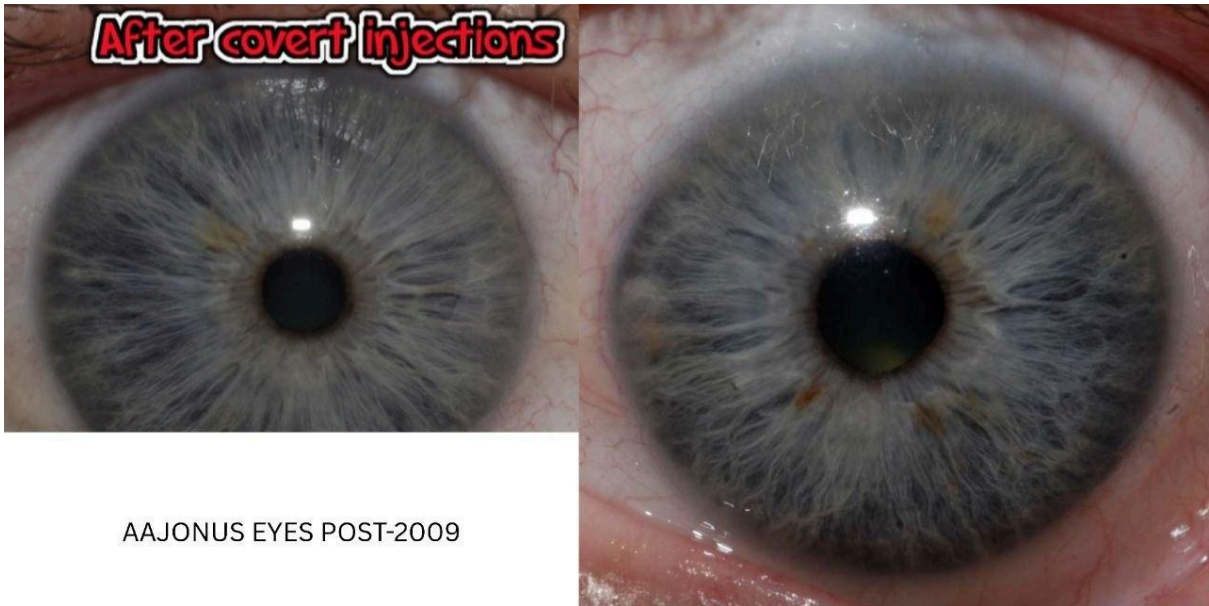

2005 (unknown % alive)

AAJONUS EYES PRE-2009



May 2007 (Left eye shows 87% alive)



AAJONUS EYES POST-2009

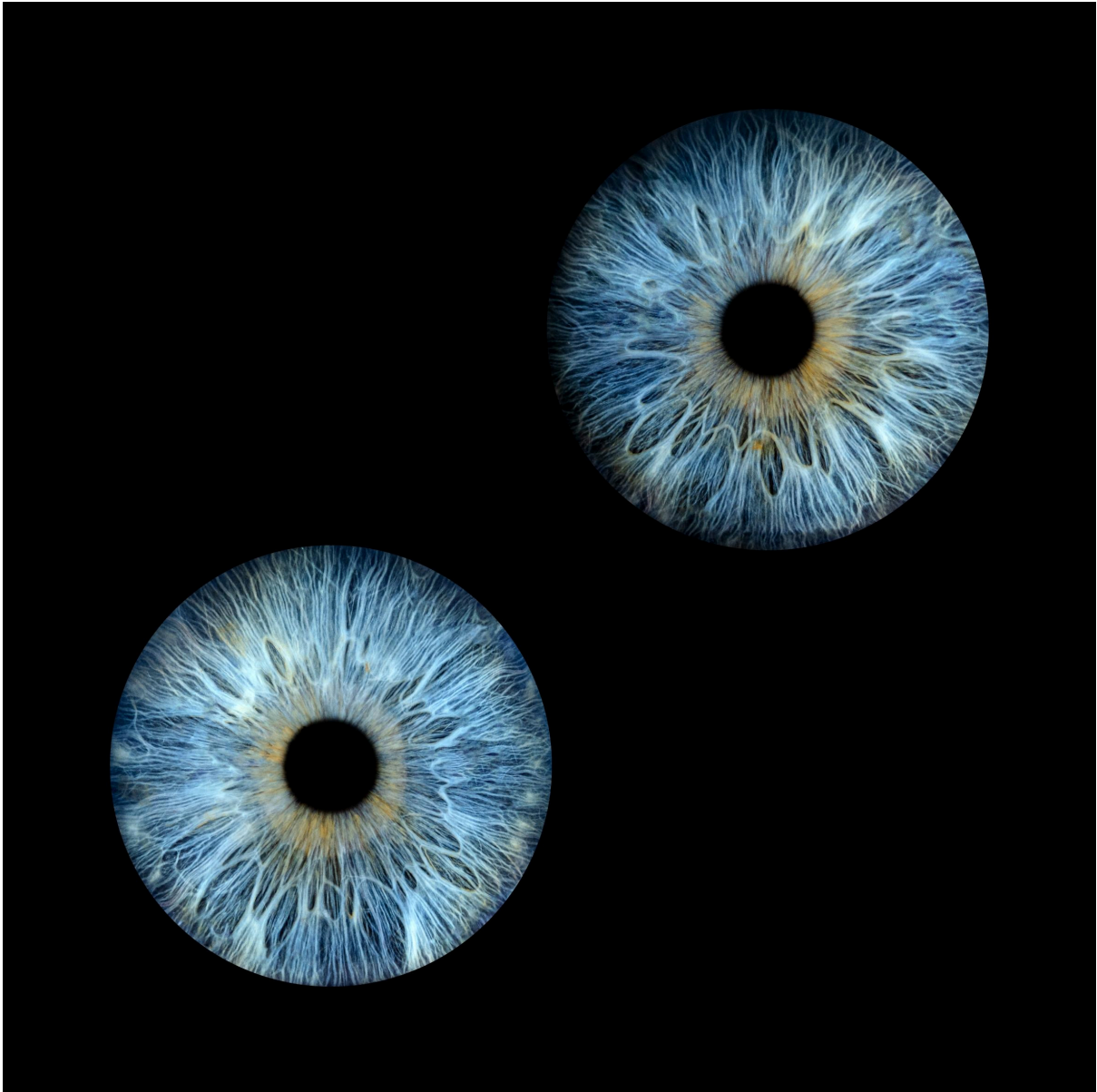June 2012 (Left eye shows 73% alive)

“In the 2012 photo, notice all of the flared and fused grayish white tissue outside the inner circle of the pupil. All of that tissue indicates mass cellular death, organic debris and scarring. My body's cellular life went from about 87% alive to about 73% alive. Although my cellular average is much greater than other people at 65 years of age, a 14% decrease in cellular life in the body is devastating. It will take about another 7 years to reverse that damage.”

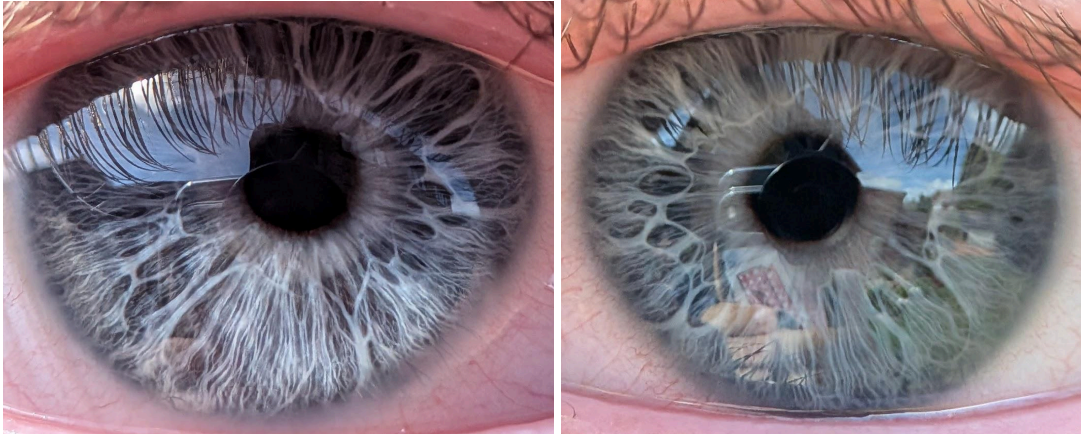
Inferences:

- Scar tissue/mass cell death, shown by white fibers, can contribute to determining if you have lower cellular life.
- As Aajonus said in many Q&As, the Primal Diet regains you 2% body function per year, backed by him saying 14% decrease = 7 years to regenerate.
- Visual examples of both 87% and 73% alive

1. General weak to very weak constitutions

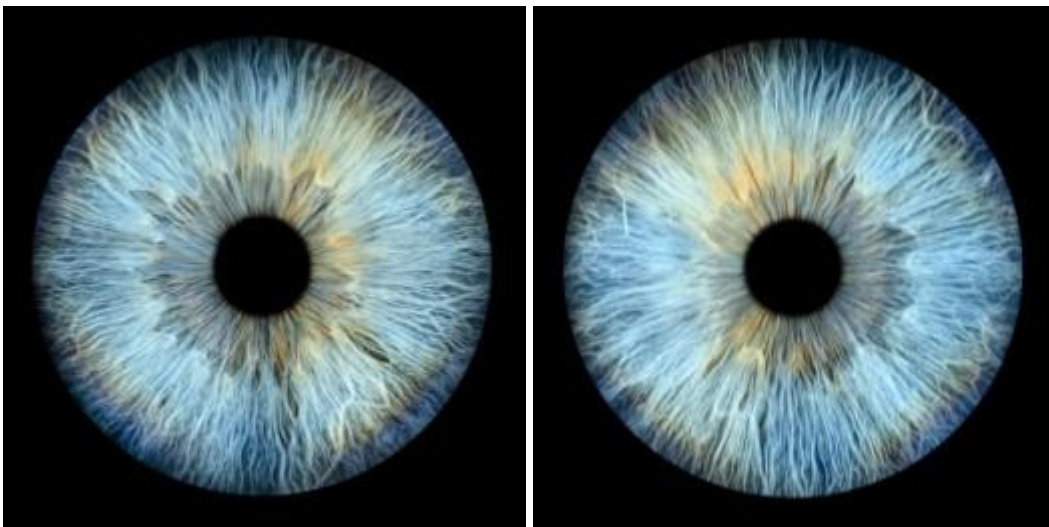


This person grew up very skinny, which can be a major factor of a weak constitution. He stopped being so skinny around age 30+. He is now mid-40s.

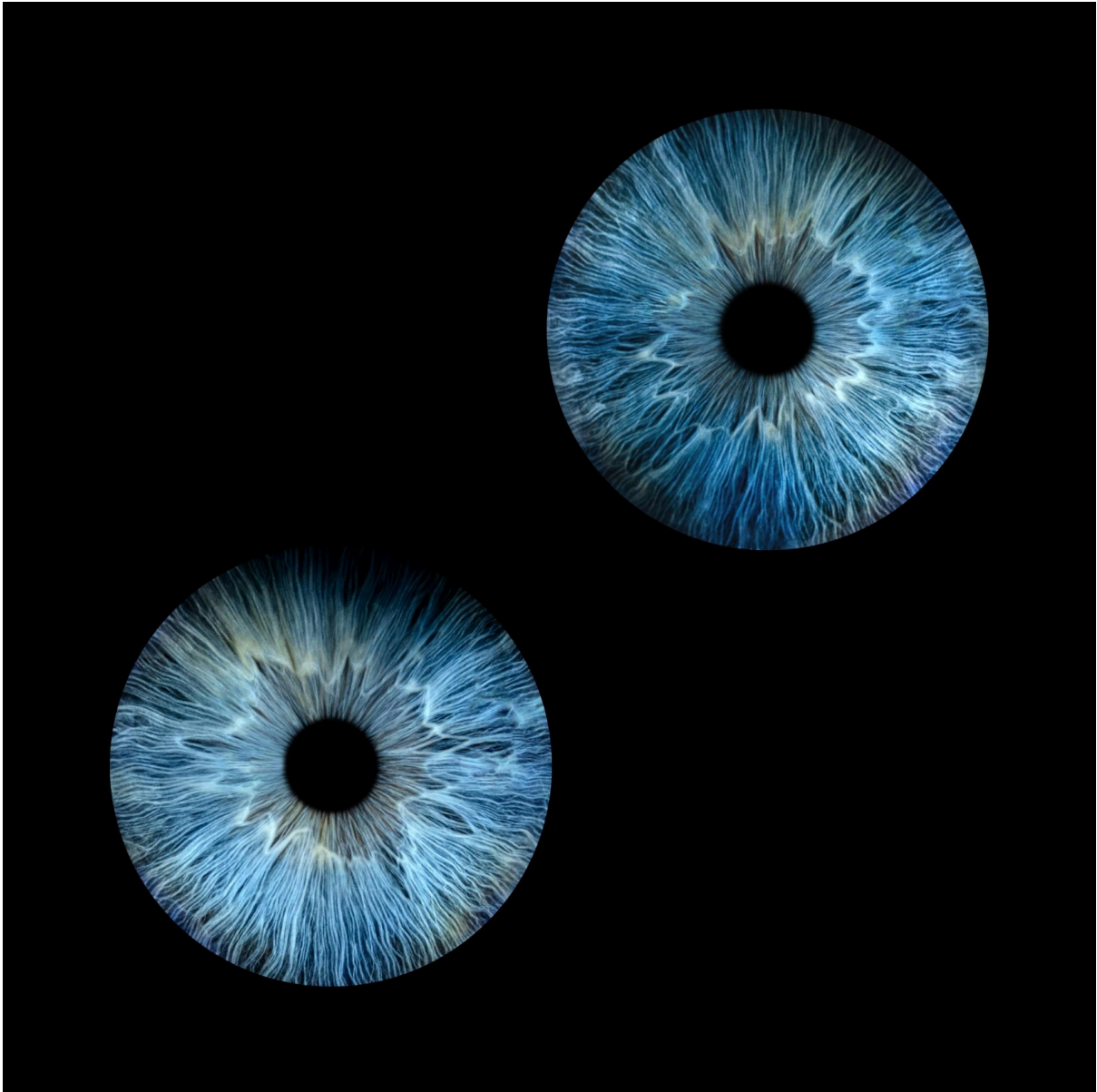


This person also grew up skinny, if anything skinnier than the previous. He is around 20 years old now, and around 18 in these photos.

2. Average constitutions

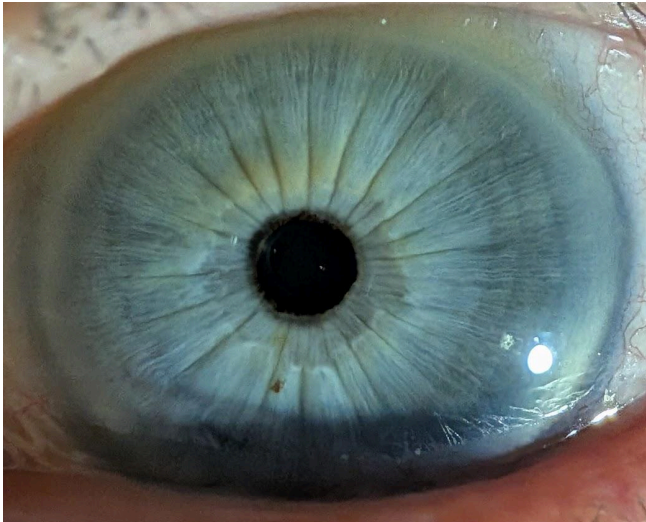

This person is me. I grew up not over nor under weight. I have some nearly straight fibers, I have some very wavy fibers, I have some transversal fibers, I have some lesions (a bit of everything).

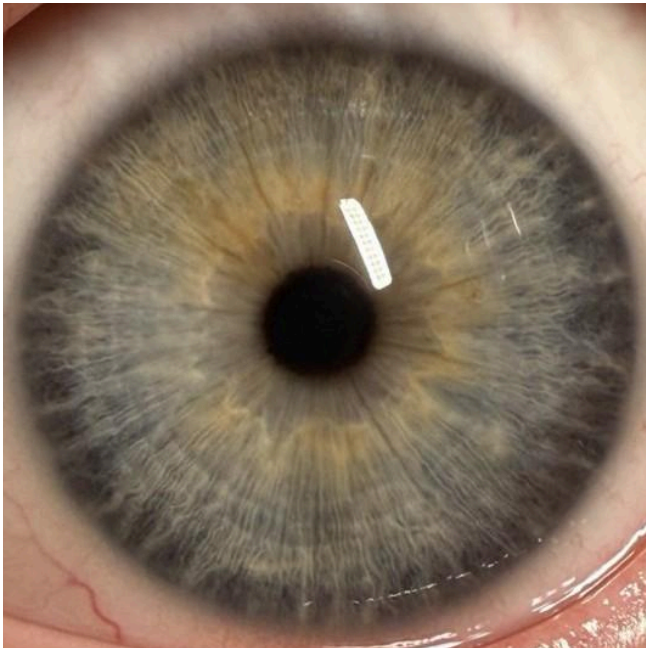


This person grew up neither over nor underweight too. She has some very good fibers in many places, some weaker areas, above average a little.

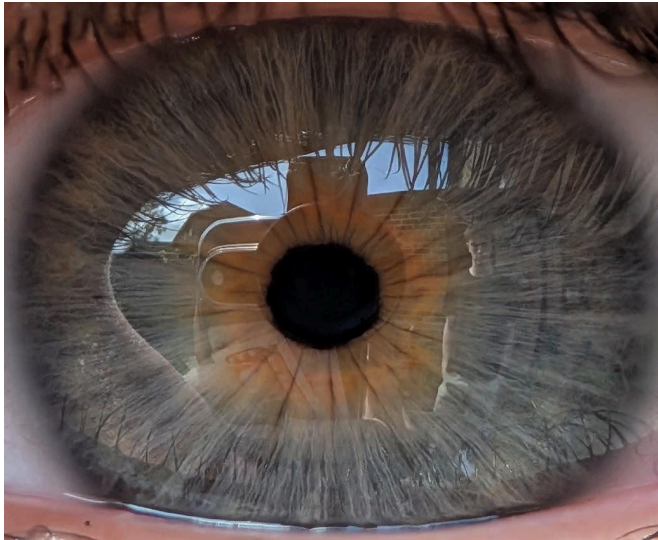3. Good to very good constitutions



This person has smoked a lot. He has an incredibly strong constitution at first glance, however, looking between every set of 2 fibers you see a grey rather than blue base, meaning a strong constitution but full of metals.

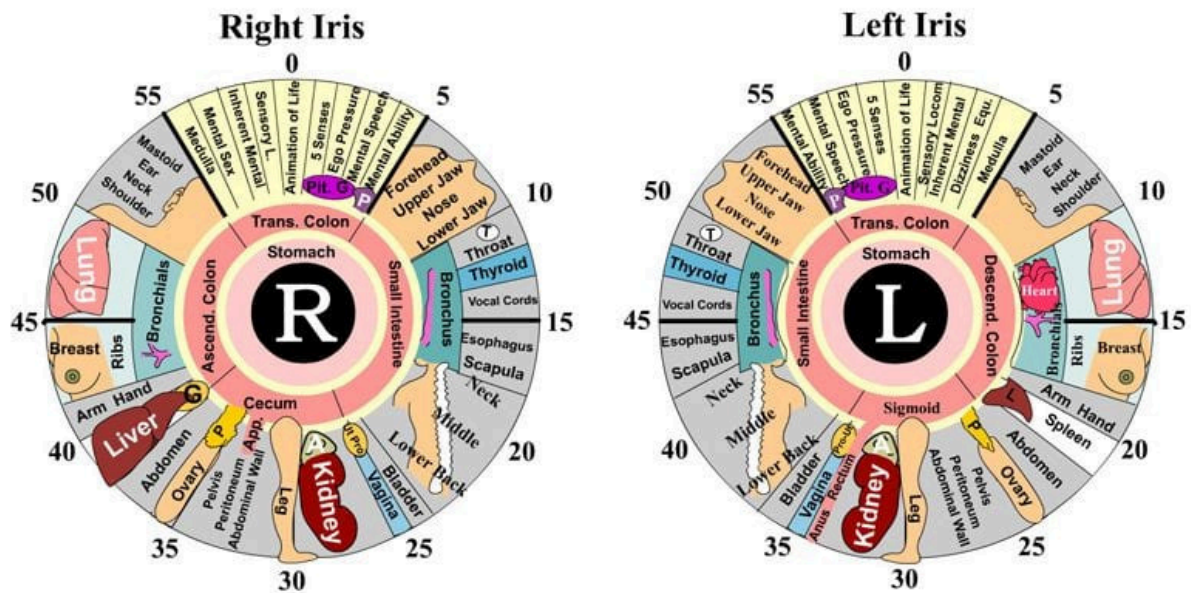


This person has a very strong constitution.



This person has an exceptionally strong constitution, but a very penicillin-filled gut area - causes 90% of IBS.

Mapping and Areas



This is a pretty accurate chart. Some quick details:

- 55 to 5 is the brain
- Ovary for women = Teste for men
- Uterus for women = Prostate for men (“Ut Pro”)
- Vagina for women = Penis for men
- Breast is just ribs in men
- Left iris doesn’t seem to include the liver
- Animation of Life = Frontal Lobe(s)
- Sensory L. = Parietal Lobe(s)

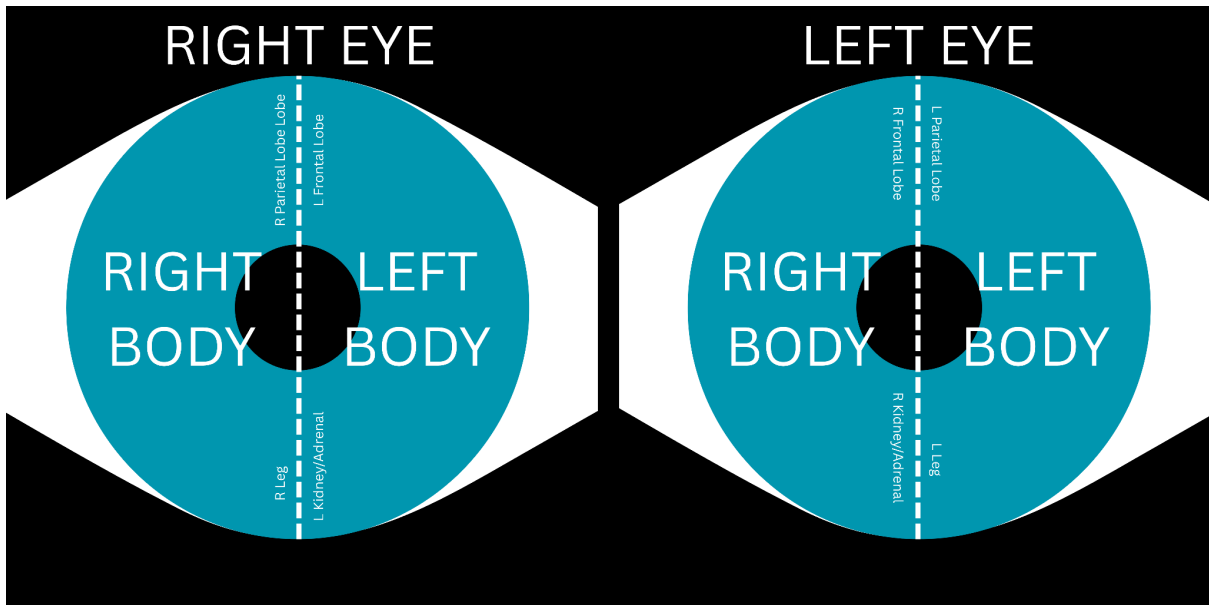
- Medulla Confirmed
- Mental Speech = Communication Center
- Any body part could be slightly different to the chart e.g. the liver could show under the hand/arm area in someone. Use symptoms to determine this. If someone has zero right hand/arm issues but problems digesting fats, it's the liver not the hand/arm.

Example: Aajonus says this brown spot in his left eye is the prostate, but with the correct chart overlaid it appears as the bladder/lower back:



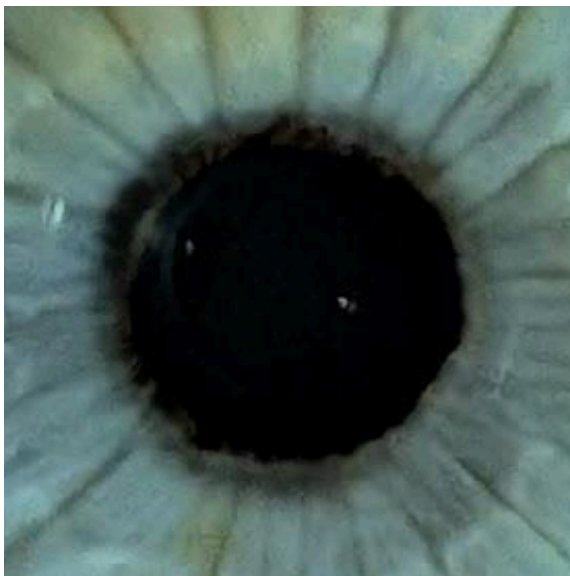
- Mastoid MAY be Skull overall?

Now some further adjustments to be aware of:



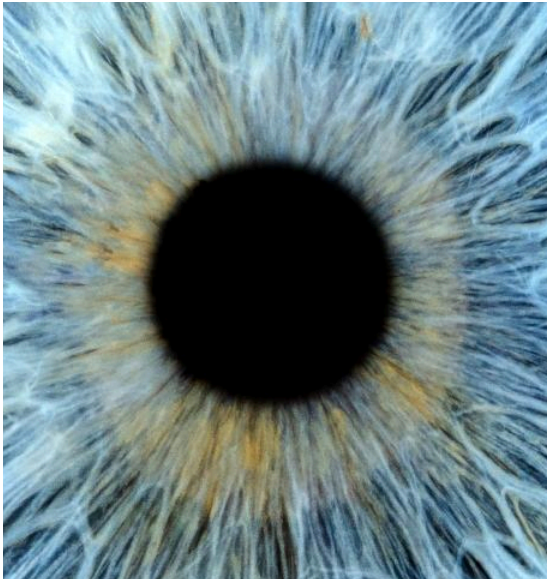
Crossing over: In most people the inner half of the iris represents the opposite half of the body. Exceptions are some engineers and almost all inventors, and this is meant to be due to their brains being wired differently.

1. Stomach - Aajonus considered the very pupil edge as well as the pupil itself to indicate the stomach. Here is an obvious example of metals in the

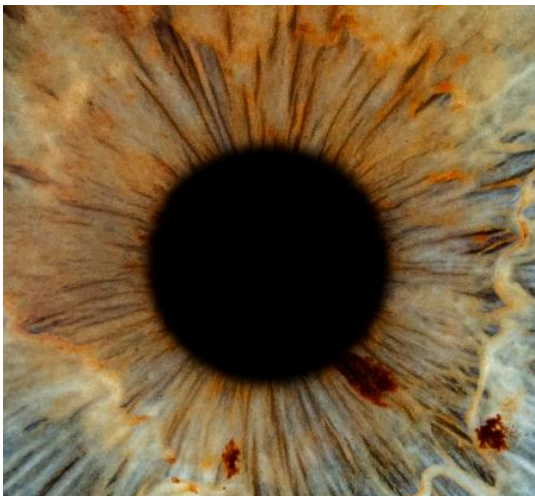

stomach lining; a grey band around the pupil border. I have not yet been able to perceive Aajonus' comment on the pulp itself, that a green tint to the pupil means industrial solvents such as formaldehyde, bleach (and perhaps other strong household cleaning products), pesticides/DDT are stored in the stomach. The only stomach sign I know of that extends as far out as the chart I gave shows, is a stomach halo that indicates

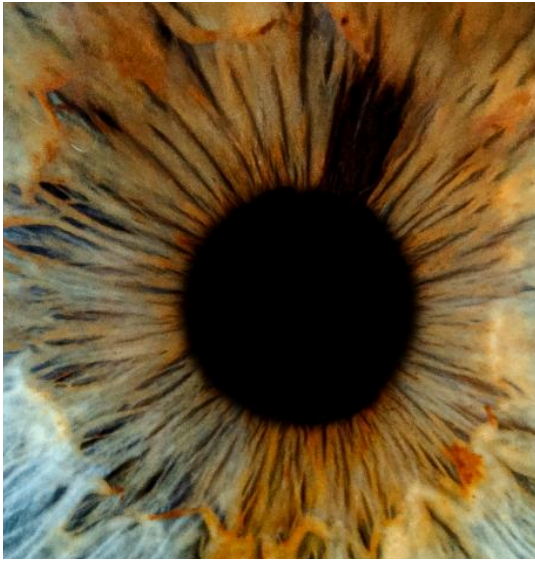over/under acidic stomach. Aajonus did not mention over/under acidic stomach as much as he mentioned acidic/alkaline blood. Below is a confirmed example of an overly acidic stomach (occasional, not chronic: indigestion, heartburn, reflux), as shown by the white halo/ring:



Here is an example of someone with chronic acid reflux who must have anti-acid tablets twice daily to prevent reflux. There is an all around slight whiteness to the area which is harder to see due to the denser yellow and orange colours. I have not confirmed what the thick black square means besides black deposits meaning mercury in that area:



Left Eye (see the right and lower sides of the pupil, you can see the white halo)



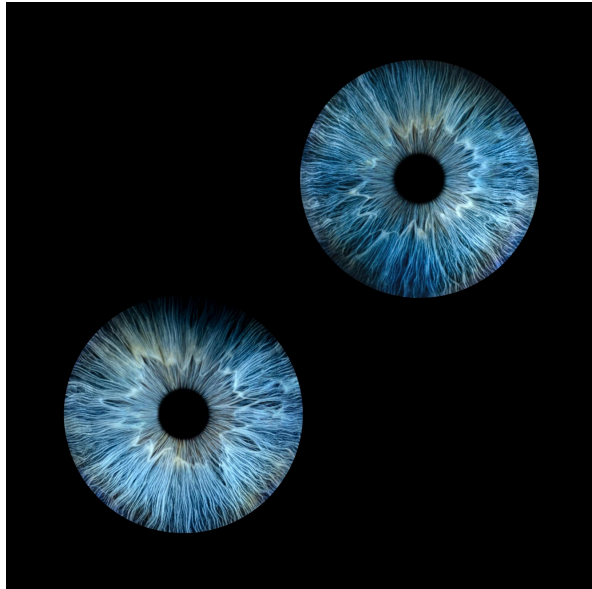
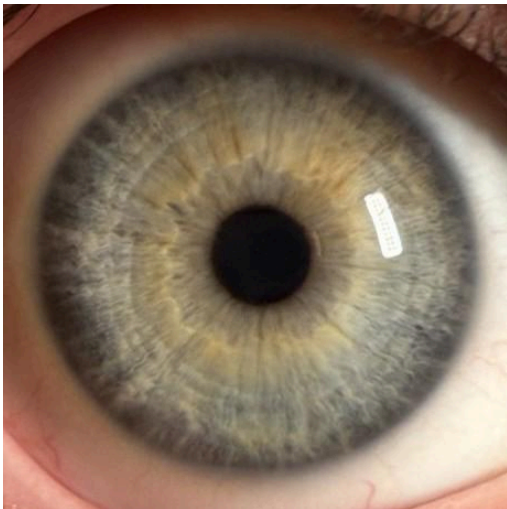
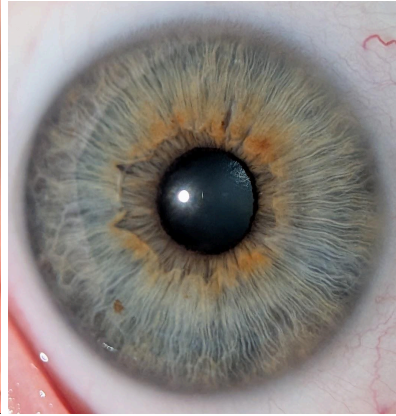
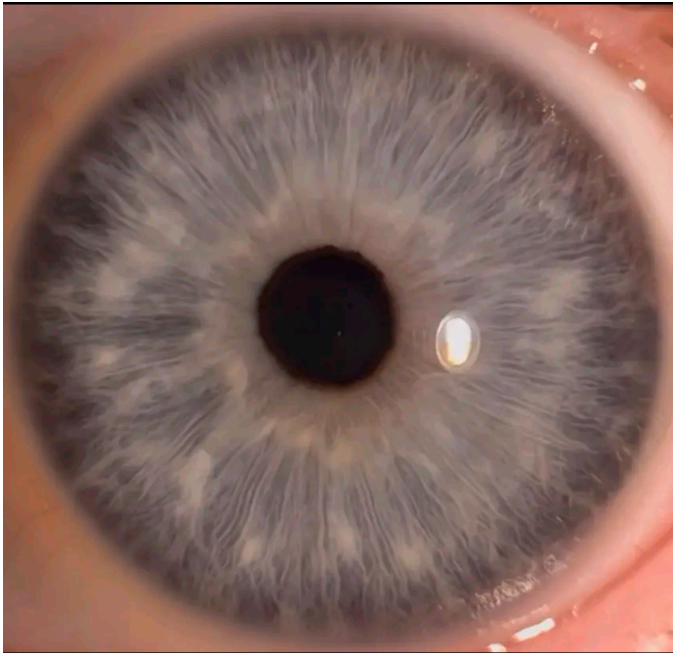
Right Eye (large black mark)

2. Nerve Wreath

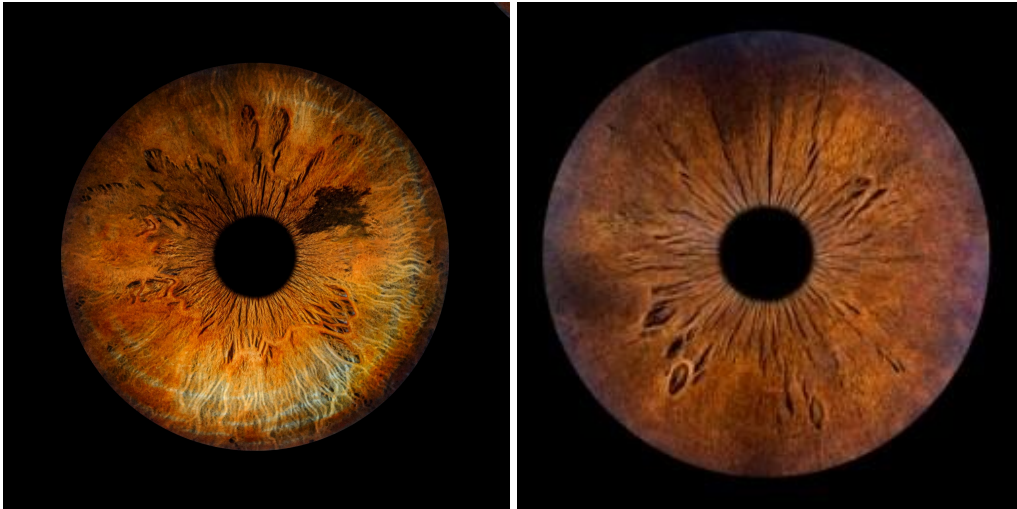Aajonus later called this the nerve belt/autonomic nerve belt/etc. like most iridologists, but in 1996 interpreted it as the lacteal system of the gut:

“This lesion is showing... that’s actually a lesion inside the nerve wreath. This little line out here he calls the nerve wreath which connects it. To me that’s the lacteal system on this side. Almost all around it’s the lacteal system. I don’t call it the nerve wreath.”

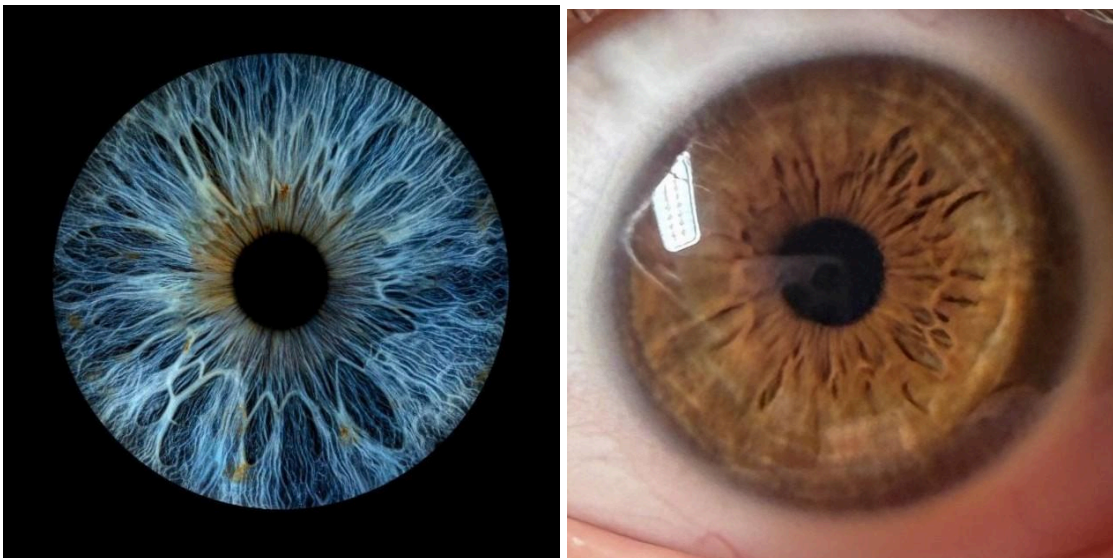
Examples of easy-to-see easy-to-trace nerve wreaths:



Examples of hard-to-see or partially hidden nerve wreaths:



Examples of moderate-to-see, but hard-to-trace nerve wreaths (require many 50/50 decisions on which line is the true nerve wreath. Often harder in weak constitution eyes):



Examples of different people with 1+ conditions/toxins

NOTE: Some of these are concrete examples with basic universal iridology, whereas others are more interpretive and require more examples to be certain. I try to label this uncertainty each time.

CONTENTS:

PART 1: Specific Diseases and their Toxins

Case 1 - IBS (and leaky gut)

Case 2 - Indigestion/Heartburn

Case 3 - Long-term Acid Reflux (1), Very Dry Skin (2), Ectopic Heartbeats (3), Prostate Cancer (4)

Case 4 - IBS (1), Liver Weakness (2), Weak/Painful Feet (3), Sciatica (4)

Case 5 - Long-term cigarette smoker (1), hyperactive (2)

Case 6 - Shorter-term THC smoker

Case 7 - Glaucoma + Medicated Eyedrops, Arthritis (1), Liver/Gall Bladder Issues (2), Bowel Polyps + Surgery (3), Thyroid-deadening (4), Pre-Diabetes (5)

Case 8 - Vegan whilst: Heavy Recreational Drug Use (1), Internal Hemorrhoids (2)

Case 9 - Mystery Early Satiety and Frequent Nausea (No Appetite/Constant Full Feeling)

PART 2: Iris Signs without Given Health Histories

Case 1 - Household Cleaning Products

PART 1

Case 1 - Irritable Bowel Syndrome/Leaky Gut

18 year old male

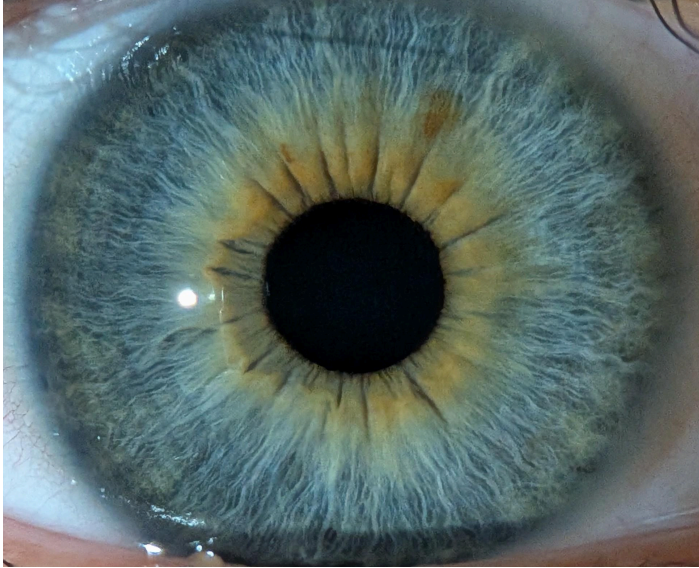
Diagnosed IBS

Iris Signs:

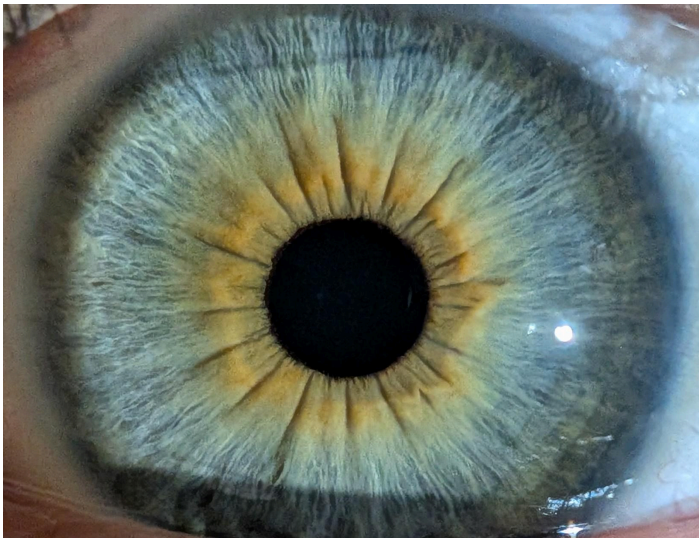
- Full and dense orange pigment around the gut area (penicillin)*
- Spikes coming out from the pupil and/or nerve wreath (leaky gut)

* “Utilizing my self-developed iridological analysis, I discovered that IBS and Crohn's mainly have been caused by penicillin and vaccines.”

Source: <https://aajonus.net/causes-for-most-intestinal-disease>



RIGHT EYE



LEFT EYE

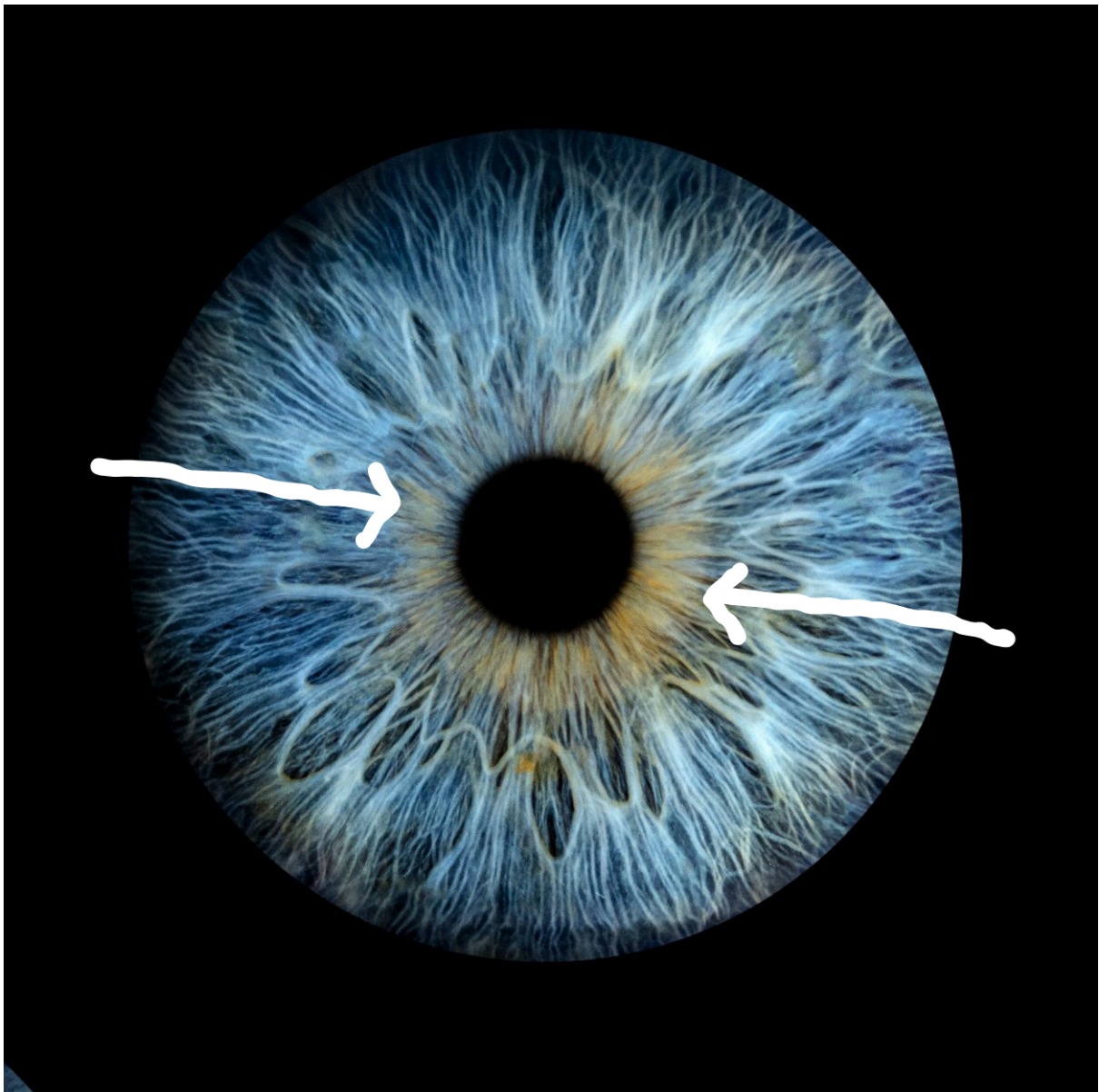
Case 2 - Indigestion/Heartburn

47 year old male

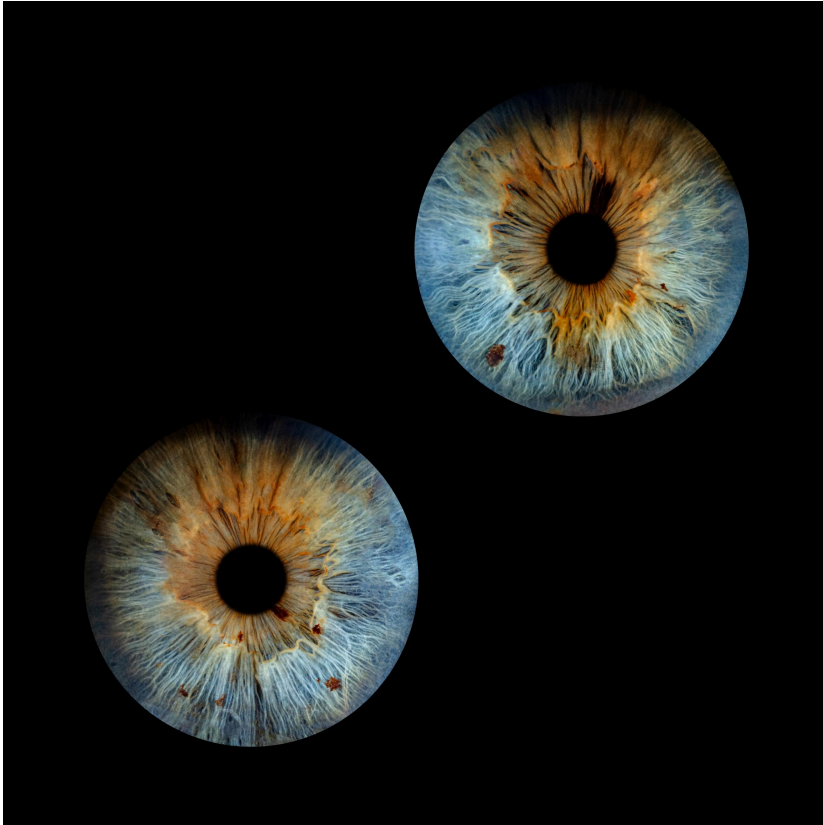Gets indigestion/heartburn somewhat often but not at every meal

Iris Signs:

- White halo around the pupil (very overacidic stomach)
- Secondary: Yellow/orange discolourations in stomach area (toxins could be released with stomach acid worsening condition, or stored there because stomach acid neutralises/destroys them)



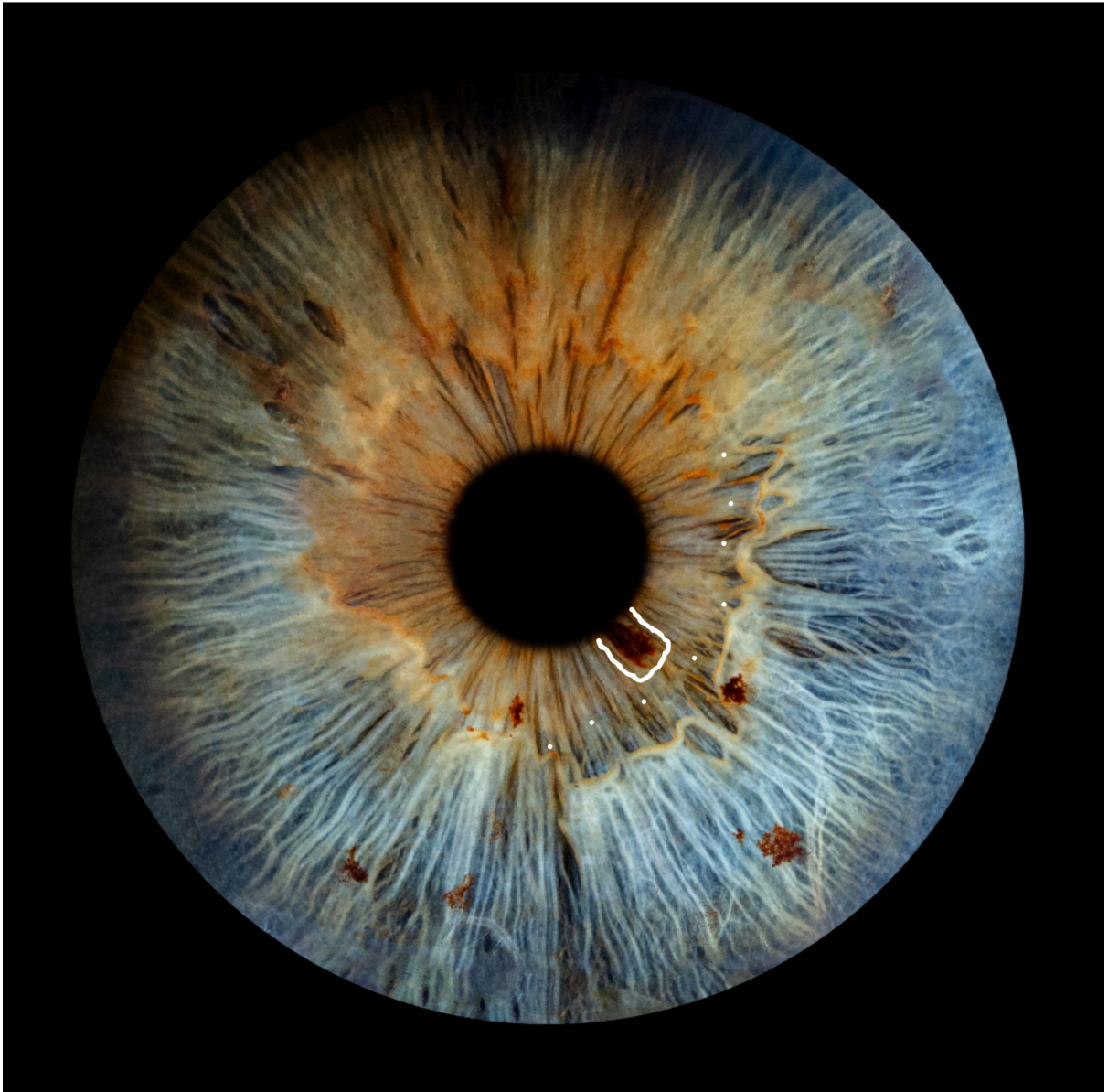Case 3 - Long-term Acid Reflux (1), Very Dry Skin (2), Ectopic Heartbeats (3),
Prostate Cancer (4)
77 year old male
Acid reflux for many years

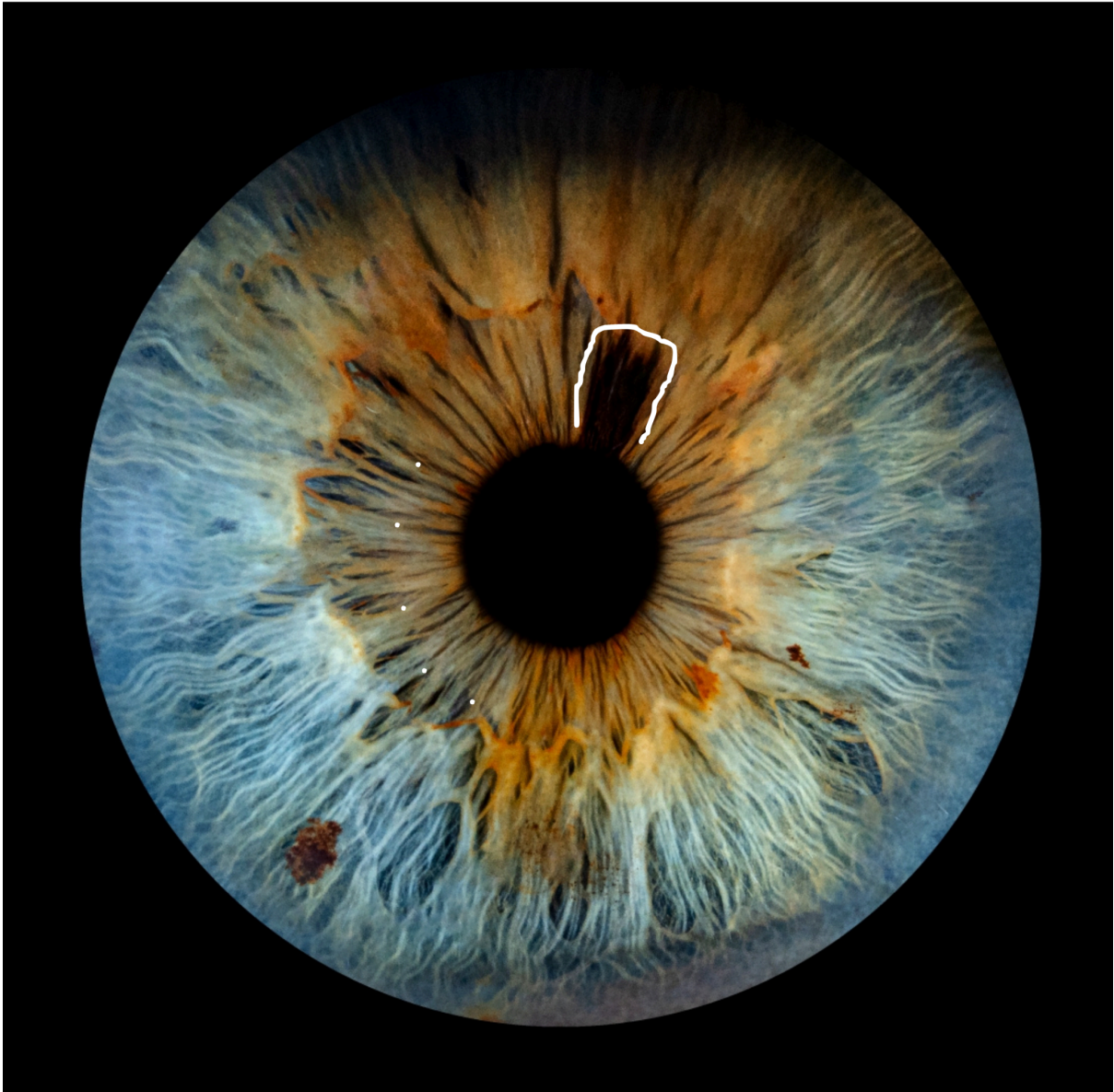

1) Long-term Acid Reflux

Iris Signs:

- White halo, less visible due to a lot more orange discoloration and less fibers
- Dark pigments, probably mercury (doesn't cause acid reflux as far as I know but will make stomach weak in general)

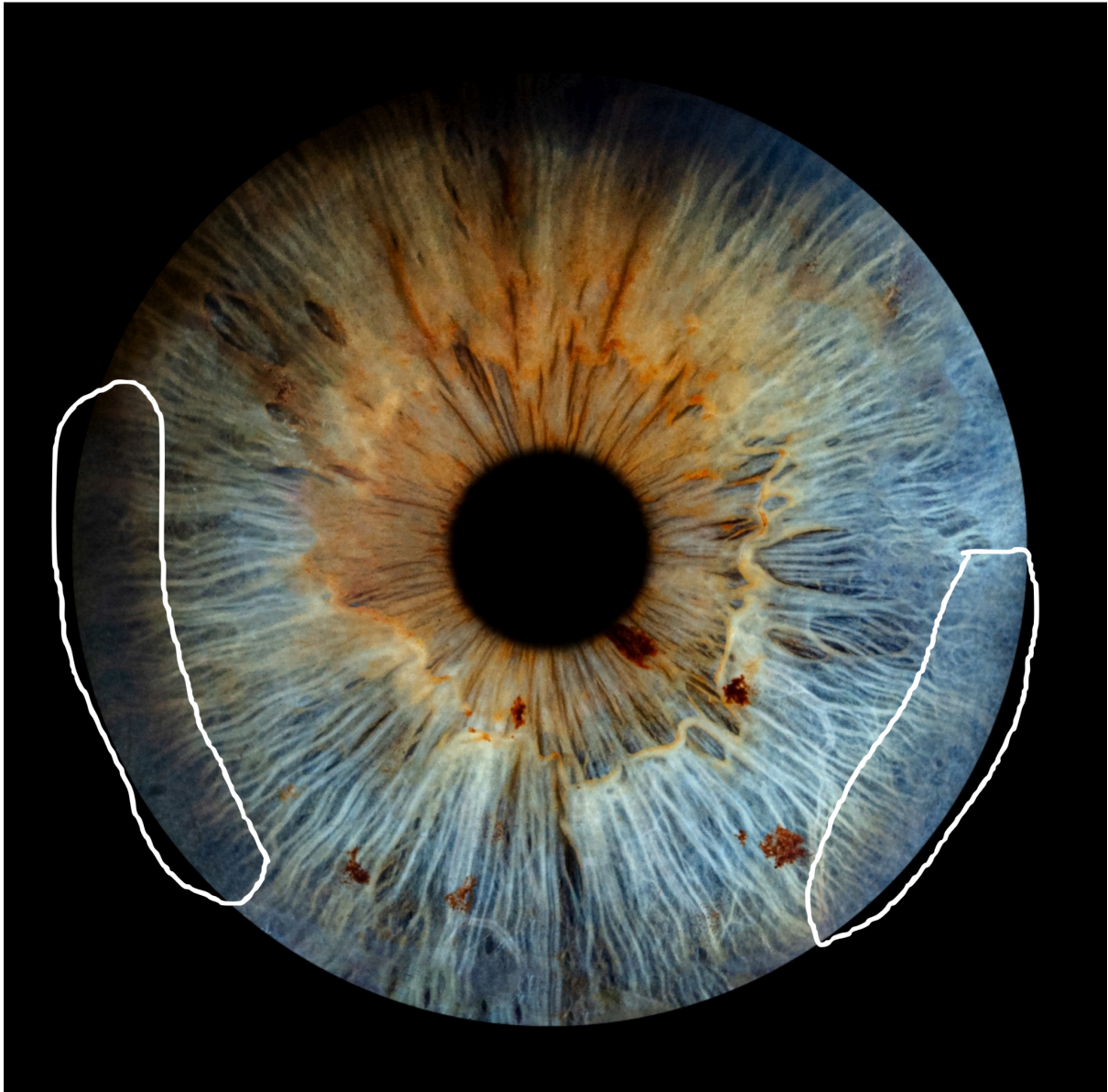




2) Very Dry Skin (observation, iris sign not directly from aajonus)

Iris Sign:

- Fibers “dissolve” as they reach the skin area, but can also be the connective tissue and lymph (remember lymph for #4)

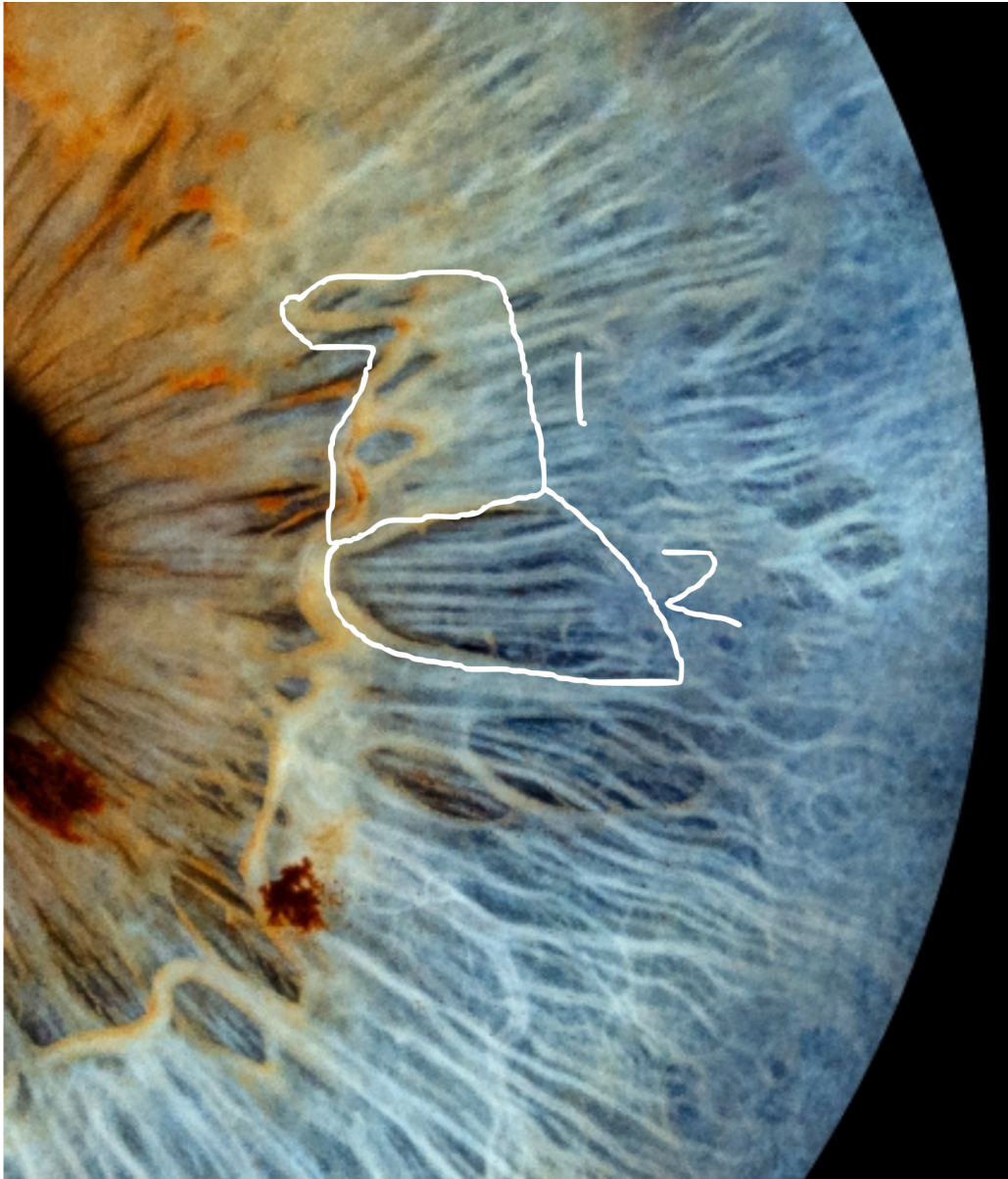

3) Ectopic Heartbeats, Very Rare Fainting

Iris Signs:

1 - Main suspect. Scarring in the nervous system adjacent to the heart. Some small lesions touching the nerve wreath in the heart area.

2 - Secondary suspect, less likely (too low on the iris). Major weak spot in the bronchioles but could be the heart if someone's iris showed it lower than normal.



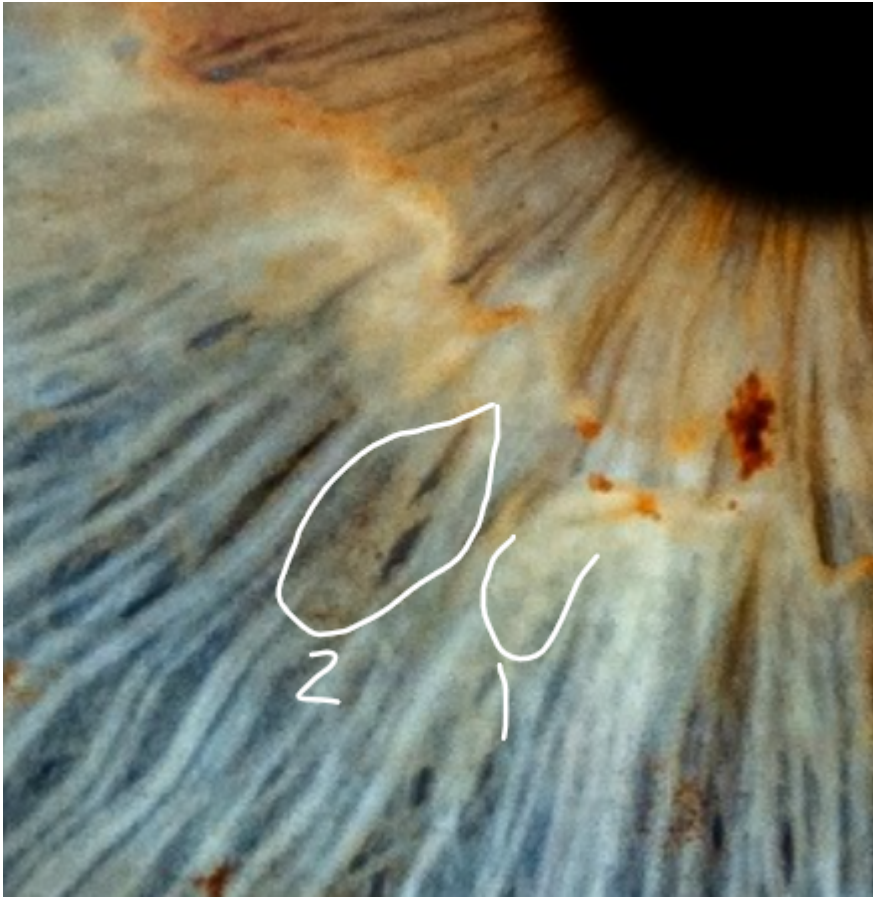4) Prostate Cancer

Iris Signs:

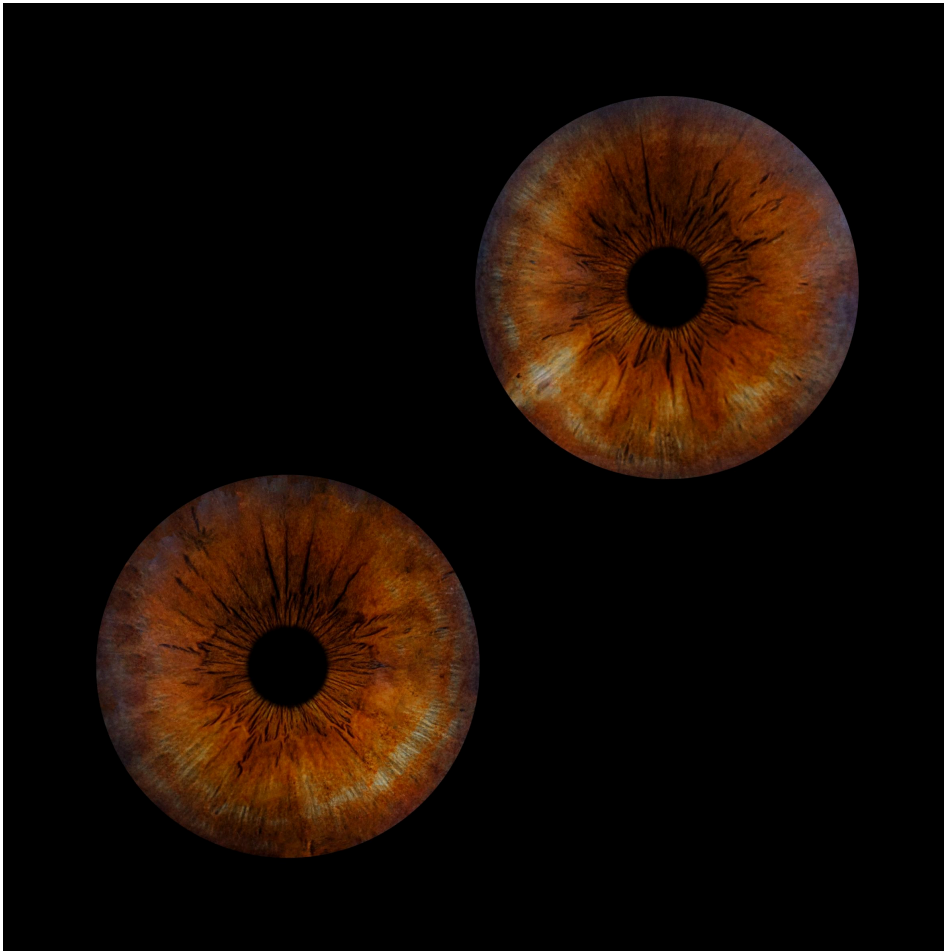
- Lots of scar tissue with little white dots in the prostate area / Major dead spot, near the prostate area (remember from page 11?)



- 1) White spots with dots in the middle, near the prostate area
- 2) Small dead spot with a lot of metal toxicity in the prostate area



Case 4 - IBS (1), Liver Weakness (2), Weak/Painful Feet (3), Sciatica (4)
75 year old female



1) IBS (not diagnosed)

Iris Signs:

- Broken fibers in the gut
- Spikes coming out from the pupil/gut area
- Especially dark gut area compared to rest of iris

2) Liver Weakness

Iris Signs:

- Whole liver area is white (mass cell death, scar tissue)
- Mercury deposit in liver

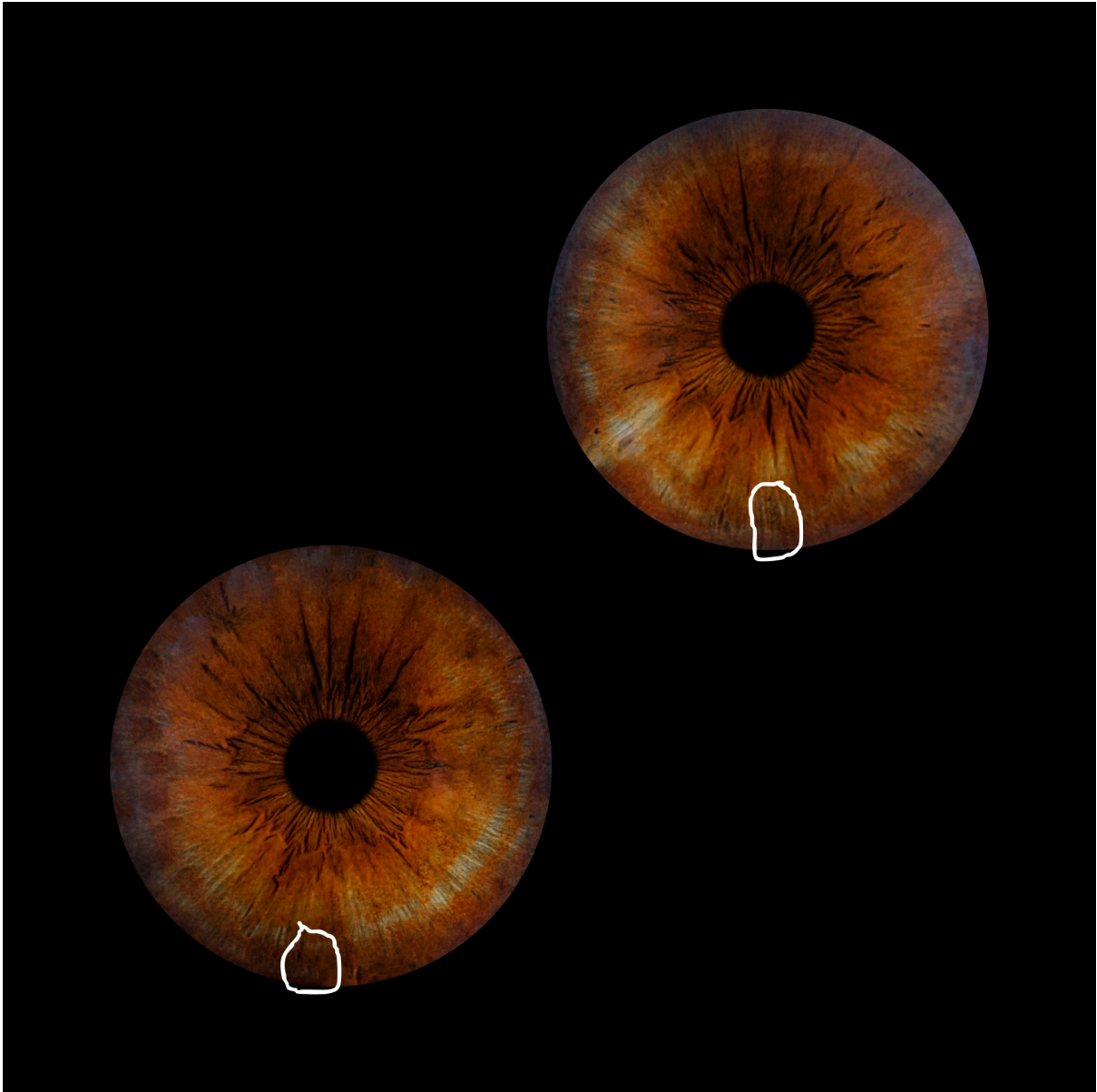
Lifestyle signs:

- Enjoys wine but not addicted

3) Weak/Painful Feet (no fat pads in soles of feet)

Iris Signs:

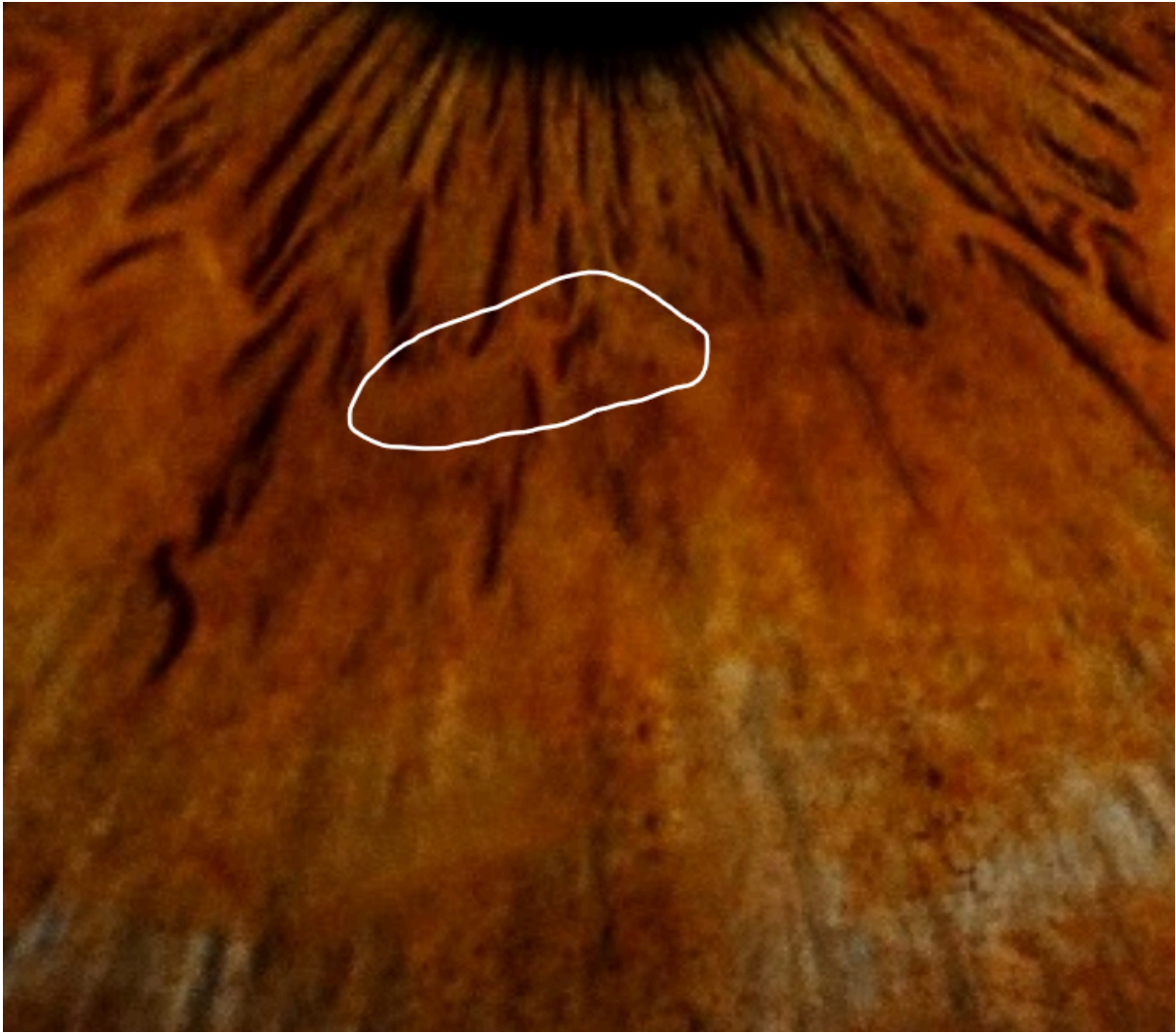- Broken fibers in feet areas (a bit of a stretch, this one)
- Mercury deposit in at least 1 foot (body uses a lot of fat to bind mercury)



4) Sciatica (left sided shooting pain down lower back, hip, leg)

Iris Signs:

- Weak nerve wreath adjacent to leg (not confirmed from aajonus)



Case 5 - Long-term cigarette smoker (1), hyperactive (2)
Late 50s/Early 60s, male

1) Long-term cigarette smoker

Iris Signs:

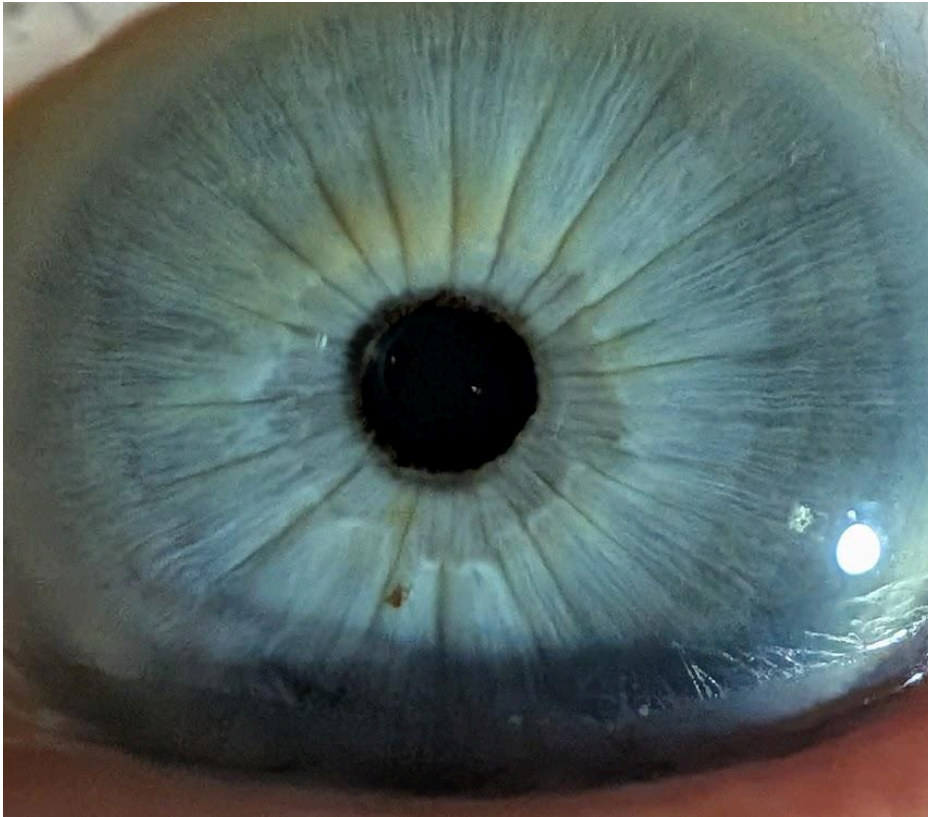- Yellow-green discolouration around the outside of the nerve wreath (my observation, I think this is smoke tars)
- Very grey stomach ring (loads of metals in stomach, cigarettes can have Mercury, cadmium, chromium, lead, nickel, and arsenic)

2) Hyperactive (always has to be doing something)

Iris Signs:

- Activity rings, seen as darker than the base blue

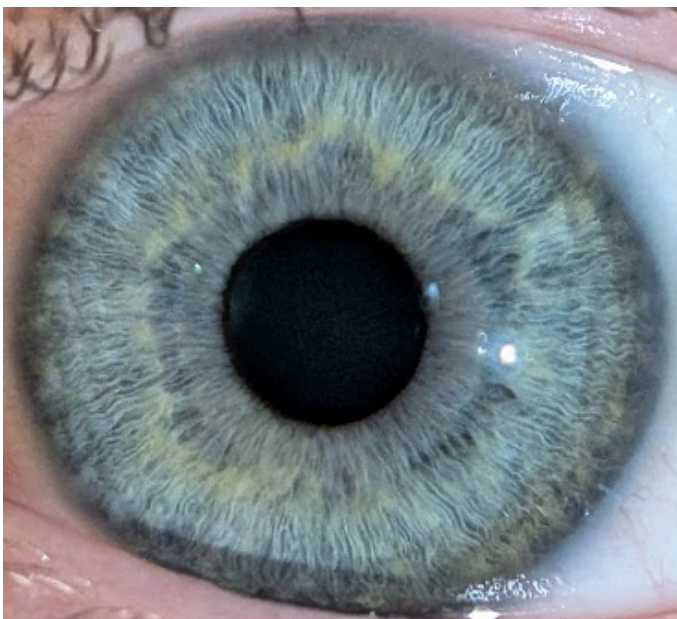
NOTE: Did not get a chance to ask about leaky gut, though the spikes indicate very strong leaky gut, maybe even leaky stomach (is that even a thing?)



Case 6 - Shorter-term THC smoker
25 year old male
A few years of THC smoking

Iris Signs:

- Yellow-green colour around the outside of the nerve wreath



Case 7 - Glaucoma + Medicated Eyedrops, Arthritis (1), Liver/Gall Bladder Issues (2), Bowel Polyps + Surgery (3), Thyroid-deadening (4), Pre-Diabetes (5)

Glaucoma + Medicated Eyedrops

See Image 1 of 2 below.

Medicated Eyedrops can cause the darkening of the iris seen only in the right eye here. This is physiological, and not iridological, in this case.

Glaucoma - The purple haze around the iris edge is reflection from the lens of the eye, related to this condition, and not from radiation (probably).

1) Arthritis

Iris Signs:

- Spikes from pupil = Sign of leaky gut (Aajonus: “90% of arthritis and rheumatism is from leaky gut. The other 10% is vaccine poisonings and other kinds of metallic poisonings that get into the joints.”)

2) Liver/Gall Bladder Issues (raised liver enzymes, previous gall stones, thick bile backing up into the stomach)

Iris Signs (darker eye, then lighter eye respectively):

- Deadening of the gall bladder
- Orange colours **could** be bile around the body

3) Bowel Polyps + Surgery (lighter eye)

- Descending colon has very weak areas
- Small blood red spots in the same area (photo taken 3 to 8 months after surgeries to remove them)

4) Thyroid-deadening

Context: Diagnosed over-active thyroid many years ago, given RADIOACTIVE IODINE to deaden a “small part” of the thyroid, now underactive thyroid and on levothyroxine.

Iris Signs:

- Both eyes show weakness in the thyroid (harder to see in darkened eye)
- Red-orange colours could partly be down to iodine too

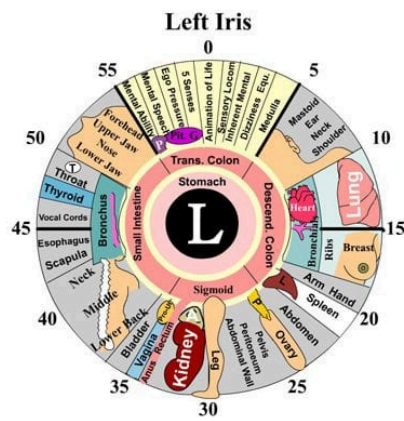
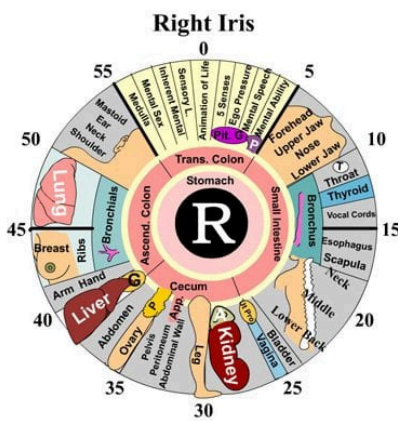
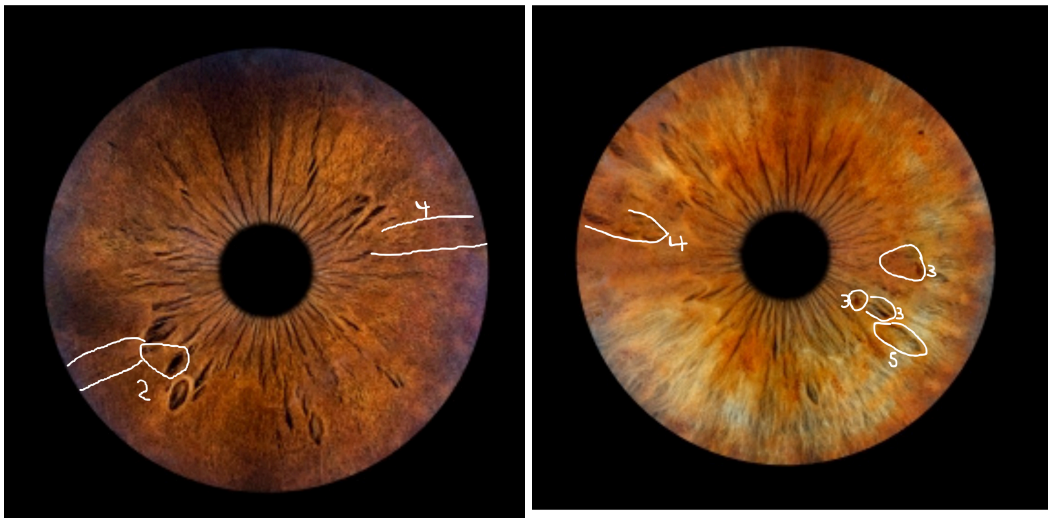
5) Pre-diabetes

Iris Signs:

- Weakness of the pancreas (?)*

*Aajonus: “So this eye [right eye] has the liver and this eye [other eye] has the pancreas. However, it shows the spleen there [left eye only on all iridology

charts], but the pancreas is over here too. I don't know where he's put the pancreas. He's put it over here [probably with the ovary/teste].”



Case 8 - Vegan whilst: Heavy Recreational Drug Use (1), Internal Hemorrhoids (2)

- 1) Drug Use (mostly meth then vaping nicotine then ketamine coke some opiates)

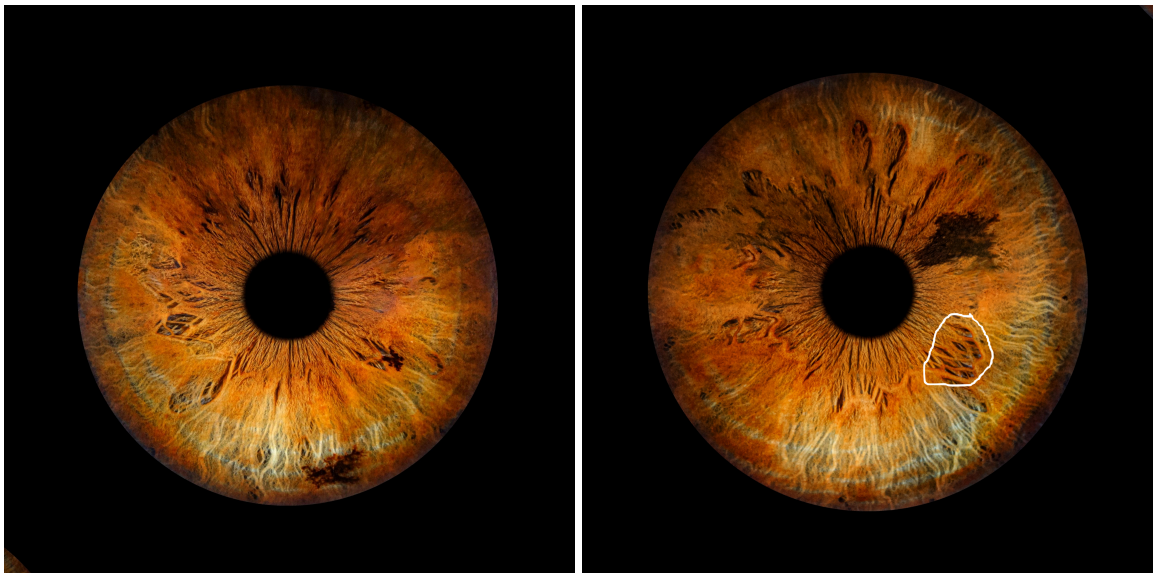
Iris Signs:

- Dark brown/black markings

- 2) Internal Hemorrhoids

Iris Signs:

- Circled Area = Lower Descending Colon/Upper Sigmoid is very damaged and has small amounts of blood red discolouration



Case 9 - Mystery Early Satiety and Frequent Nausea (No Appetite/Constant Full Feeling)

This is an ongoing client who did the diet (raw: meat, cream, milk) without vegetable juice or cheese for 1 year. Now, for 1-2 years, he has had a very low appetite not fixed by any of the normal recommendations such as more vegetable juice, papaya/papaya custard, etc. It started one random day upon waking. Note it was 4 months after a chest x-ray but that is probably unrelated. He also gets nauseous from most foods with the exception of celery juice.

He notes never having antibiotics so it is extremely unlikely to be penicillin.

Theories I suggested based on other experience and iridology:

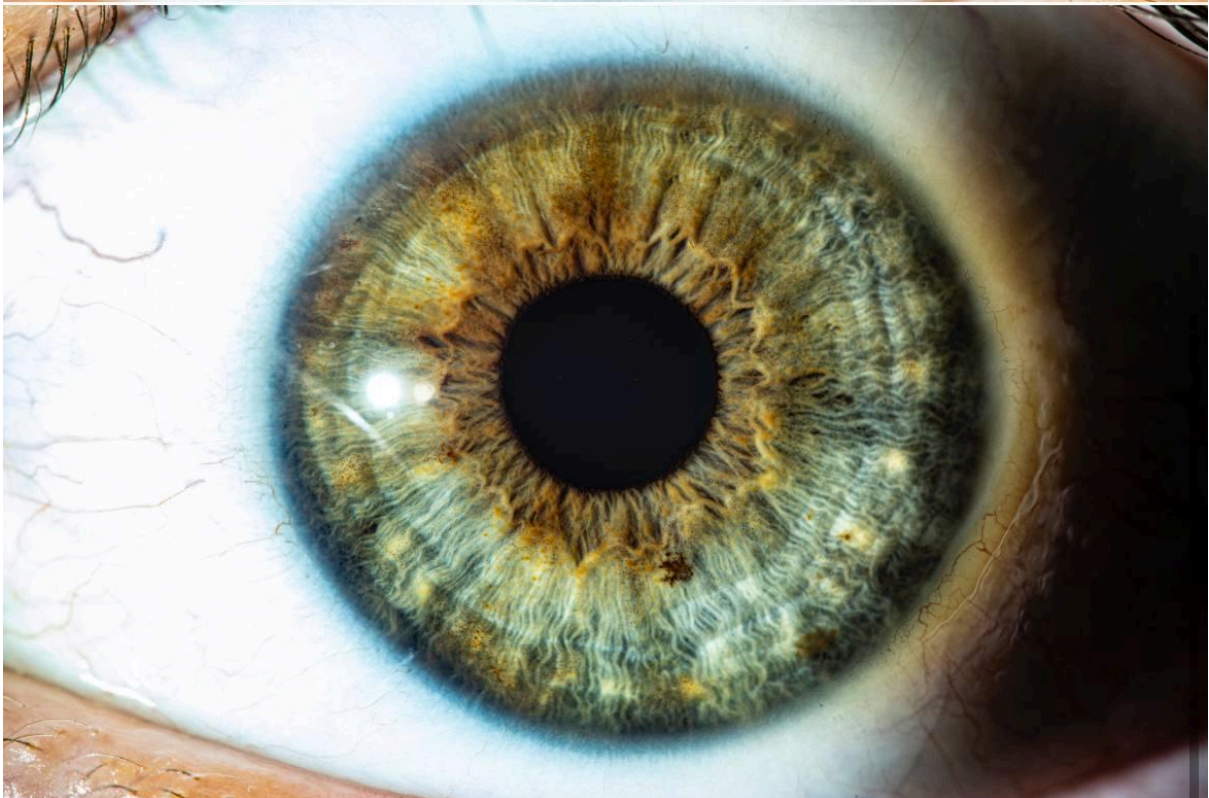
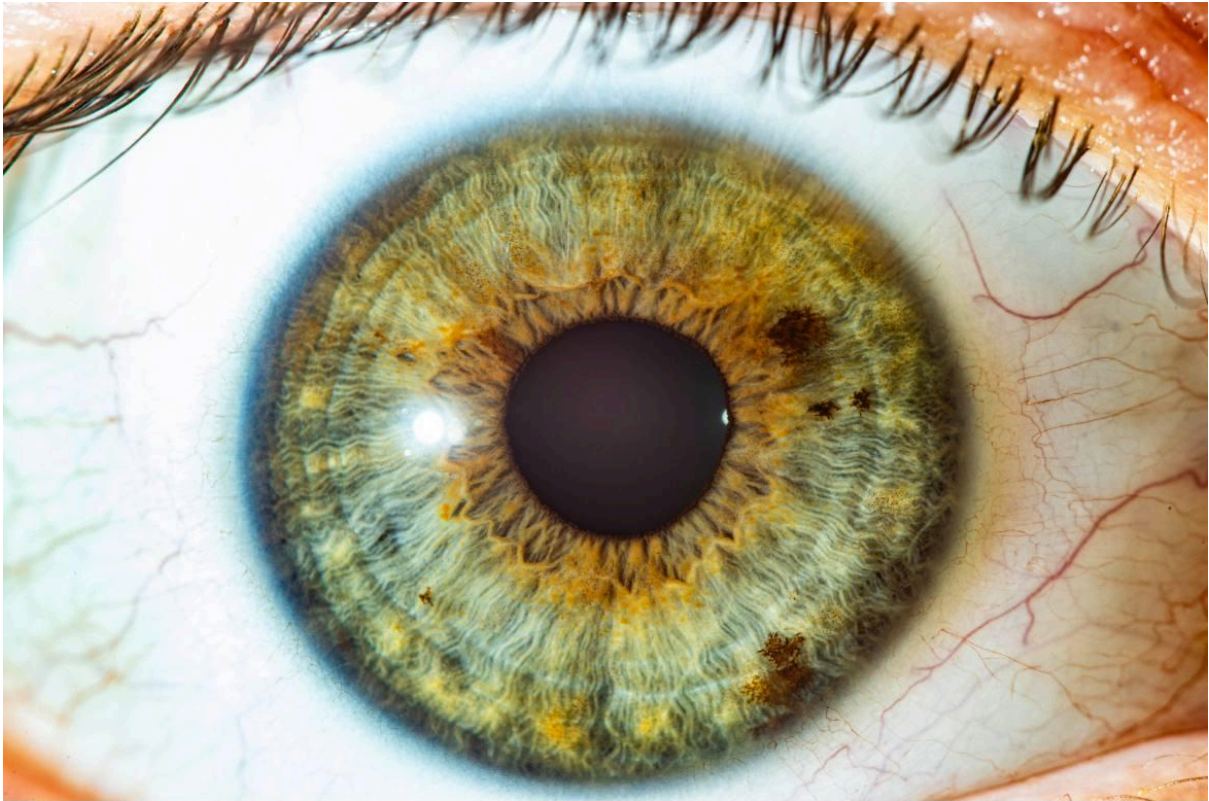- 1) LIKELY: Bile - Aajonus mentioned to a client “Looking at your iris photos, I see that the bile throughout your system is not bound with as many solidifying compounds as with most people.”

“If the liver malfunctions, you could also be at the other end. Anorexic, inability to eat because you're so acidic. You're nauseous all the time because acidity dumps into the stomach. Then you get nauseous because your body has a tendency to want to vomit when all those poisons dump into the stomach. So then you have no appetite. Those are the two extremes of reactions or symptoms from a faulty or toxic liver.”

Evidence pointing to bile as causative:

1. Grew up skinny
2. Ate a lot of cooked starches
3. Orange colours throughout iris (not confirmed by Aajonus but you would expect bile to show as an orange/yellow)
4. Frequent nausea from animal foods
5. No appetite
6. Able to drink lots of vegetable juice (alkalising)
7. Palms show some yellow
8. Palms show weak liver

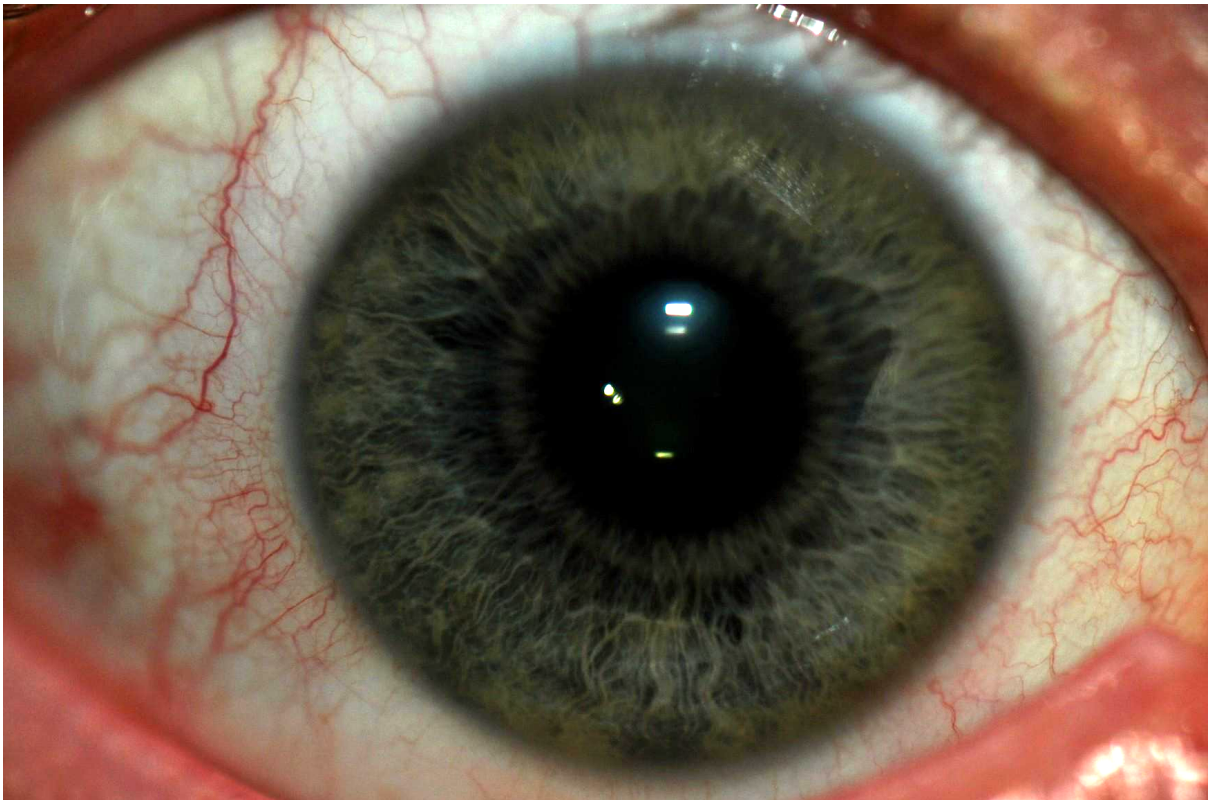
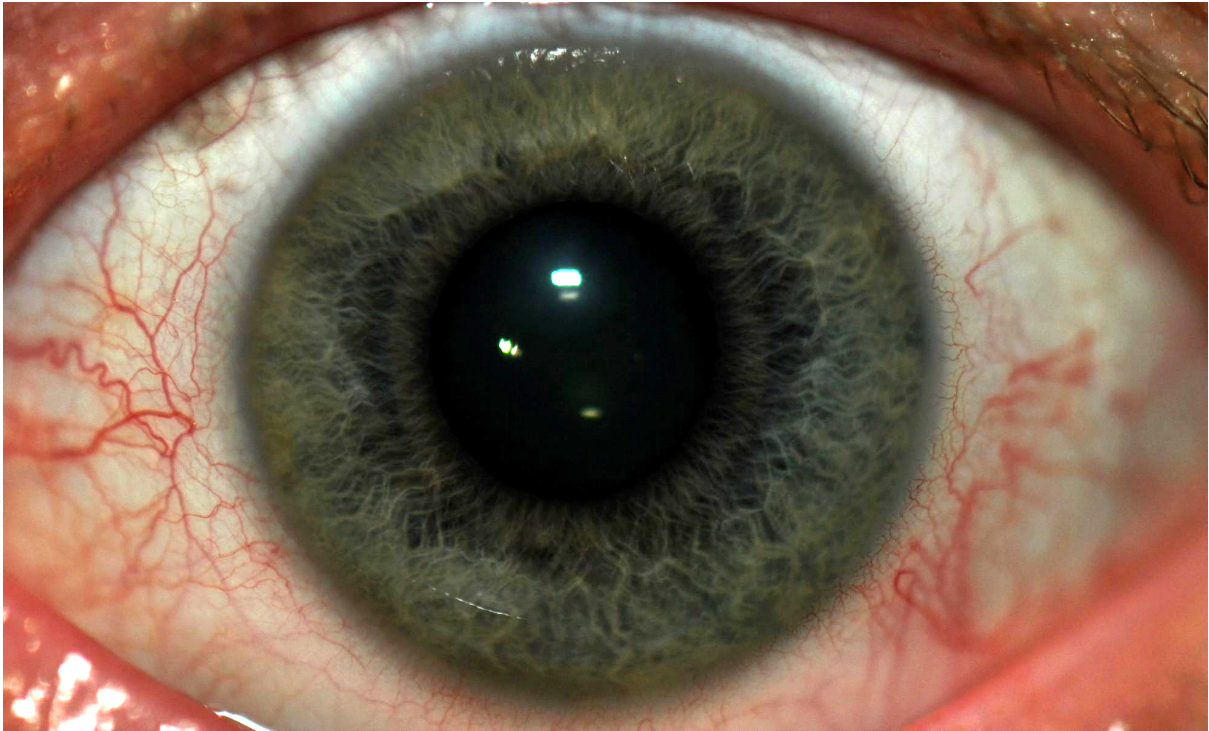
- 2) UNLIKELY: Mercury in Esophagus - In the first image (right eye) at around 2:55 there are 2 black spots. In older images they appeared more at 3:05 so would now be placed in the vocal chord, still a part of the throat. My theory was that after a year of a raw animal based diet, the body began dumping mercury to be bound with fats. Most nausea was solved with vegetable juice though, making this unlikely due to mercury being buffered with fats not alkalinity.
- 3) UNLIKELY: Aluminium in gut - There is some silver-lavendar colour in parts of the gut/stomach, along with the chest x-ray 4 months prior could cause radiation damage to gut, the detoxification of which causes nausea.



Case 10 (AAJONUS CONSULT 2013) - Mercury-Filled Intestines (1), Crohn's Ring (2), Metals in Bone Marrow (3)

- 1) Mercury-Filled Intestines - The gut area is (almost) as black as the pupil meaning it is FULL of mercury. Aajonus mentioned one client who had so much mercury in the stomach and intestines, he thought the guy would have to eat cheese all day the rest of his life so as not to poison himself. The guy ate 10x the amount of cheese Aajonus recommended and removed 60% (or 90% in other Workshops/Q&As) of the mercury in 1 year. This may or may not be the same guy but it seems unlikely there would be more than one of him. The odd thing is that this consult says it was done in 2013 but Aajonus could not have followed up on it since he died. Also, mentions of this guy go back earlier to 2012, meaning he must have had at least 2 consults before 2013.
- 2) Crohn's Ring - It's hard to tell for certain which iris sign this means. It could be the white halo around the pupil, which is also a sign of over-acidity of the stomach, usually.
Alternatively, it could be the thin/absent "nerve wreath". Alternatively again, it could be the subtle white dots along the "nerve wreath".
- 3) Metals in Bone Marrow - Look closely. There is not only a blue halo around the iris edge, but also blue tinting of the sclera further out in each direction.

"Lots of aluminum and tin in your bone marrow. And that obstructs the cell's ability to develop properly, so as much as you have in the bone marrow, probably is obscuring about eighteen percent of your energy level. Right off the bat. And if you've got that laptop sitting on your lap and charging those with that EMF field, that metal in your bone marrow is going to double it. Double and triple. Every cell that's created during that period."

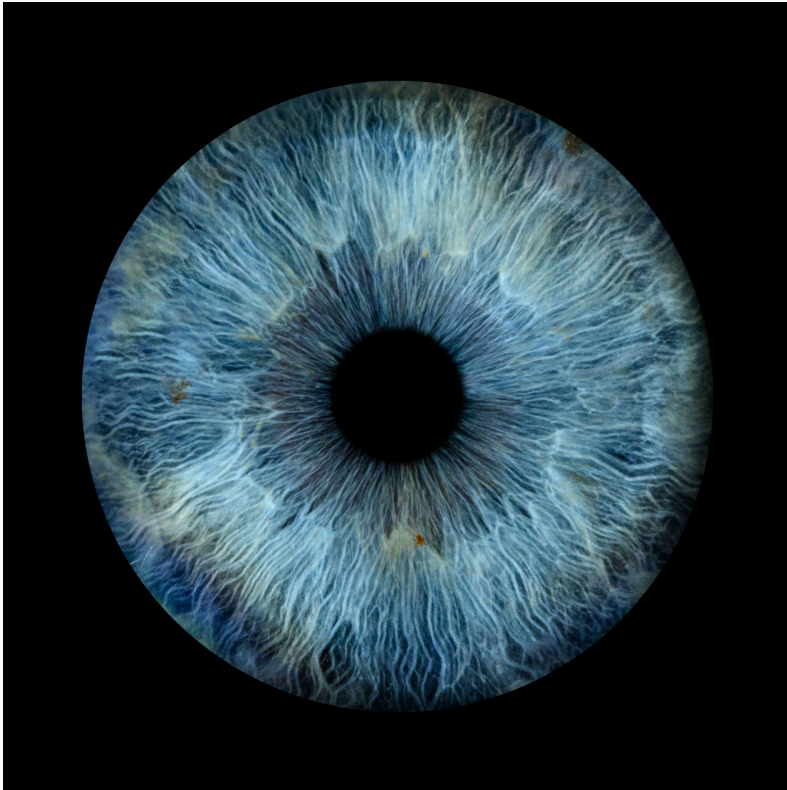


PART 2

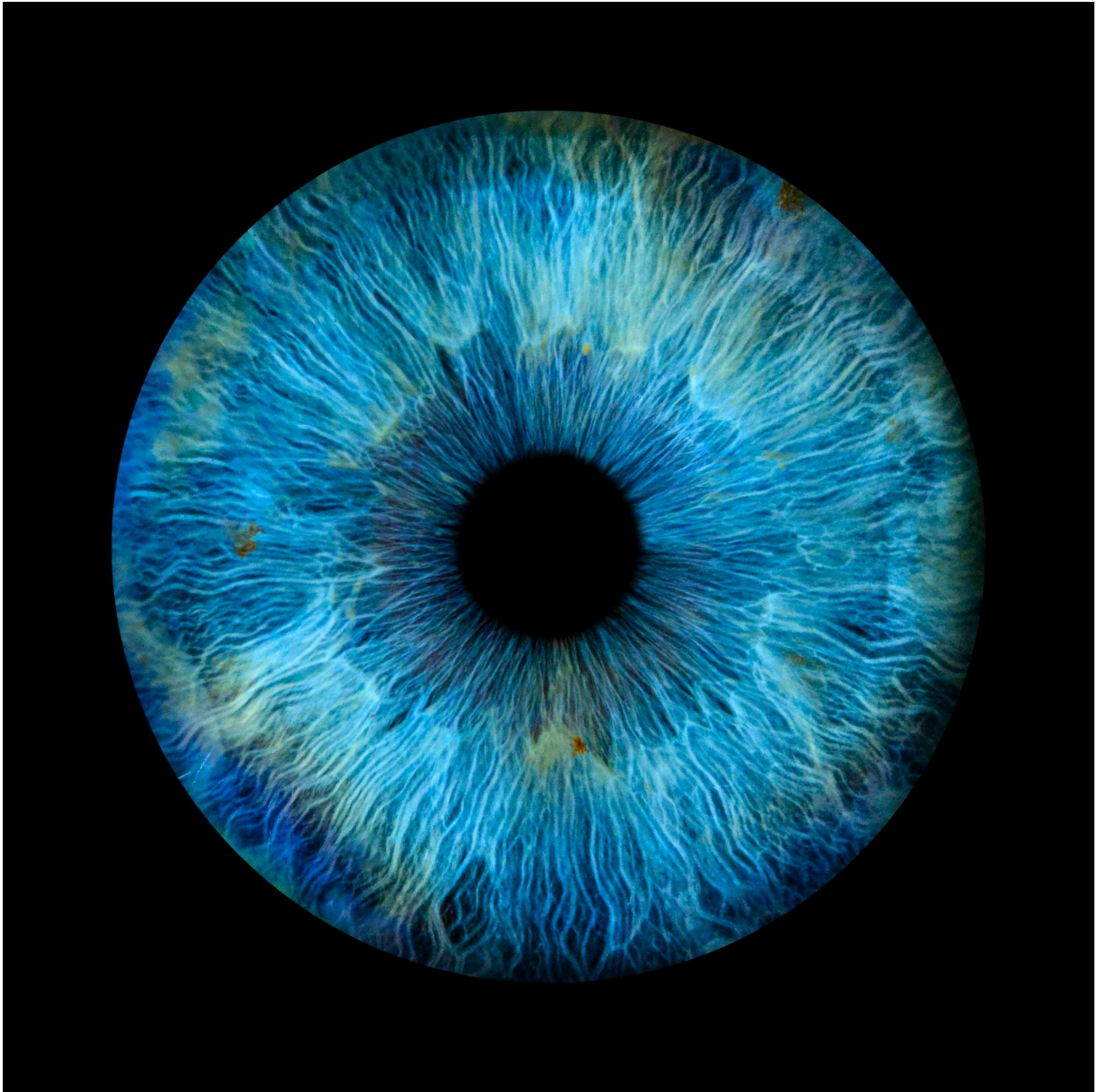
Case 1 - Household Cleaning Products

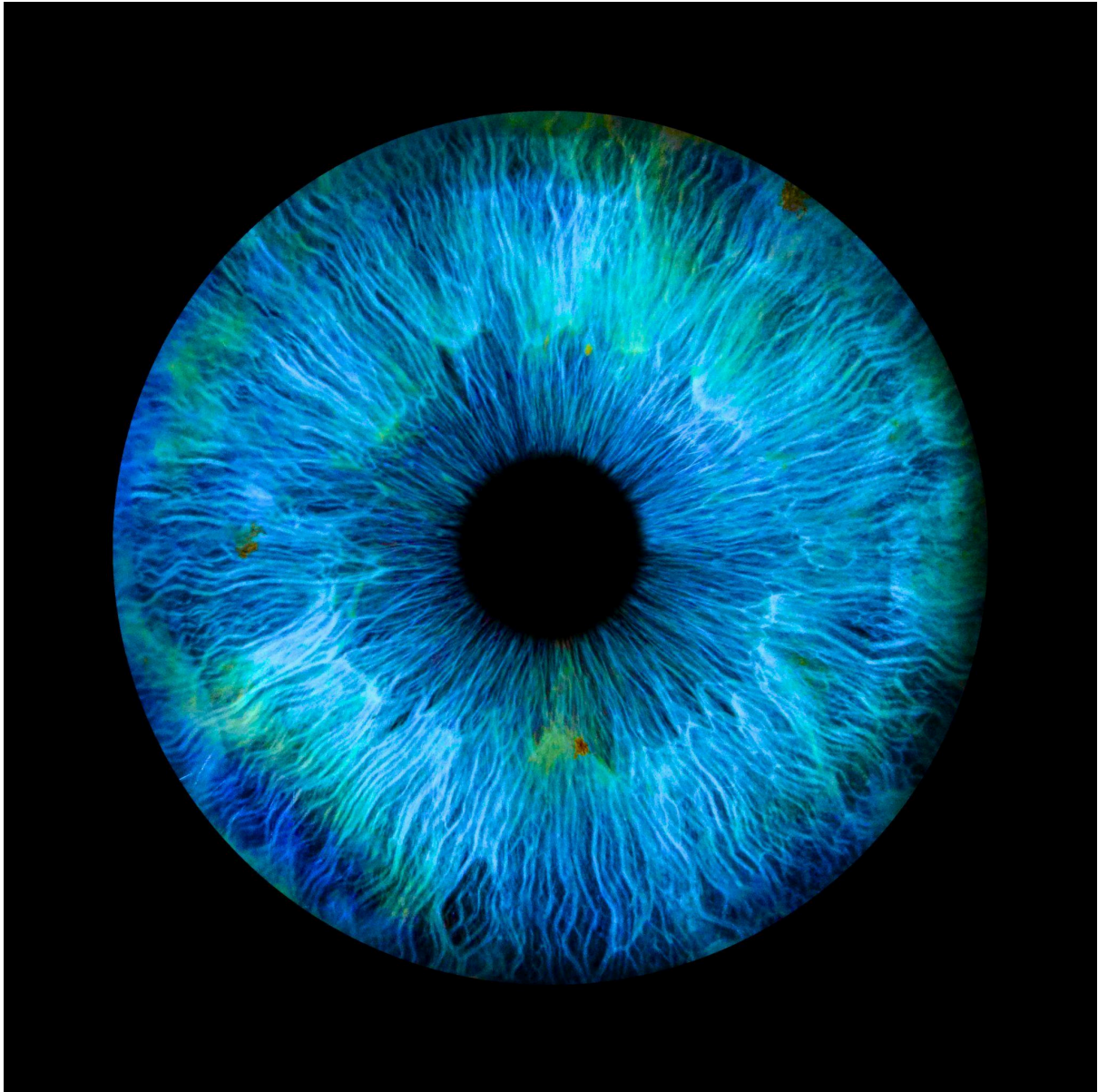
20s, Male

During childhood mother cleaned house with chemicals daily



Don't see the green? I didn't either at first. Here is 100% and 200% increased saturation:





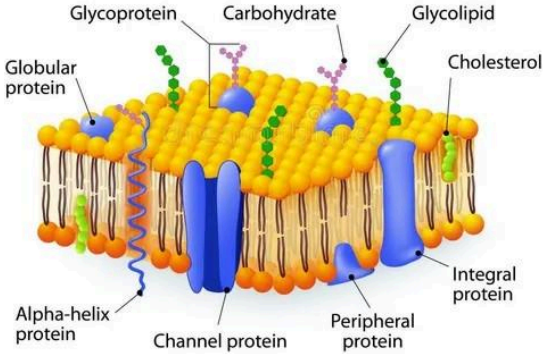
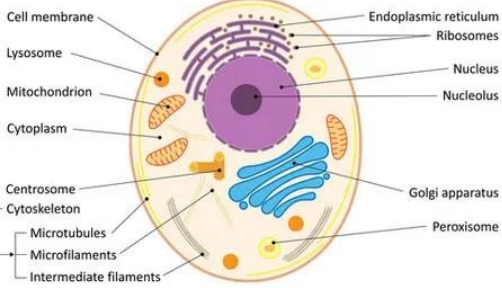
This one is a bit of a stretch and is only $n=1$ so far. Needs more testing to be sure. I deduced this conclusion by ruling out:

- Arsenic exposure
- Pesticide/DDT/Industrial Solvent exposure
- Antibiotic exposure

Therefore I came to the conclusion that household cleaning products are a pale green tint, but again this is $n=1$ and needs more results to be sure of.

Iridology vs Palmistry

Iridology	Palmistry
-----------	-----------

<h3 style="text-align: center;">CELL MEMBRANE</h3> 	<h3 style="text-align: center;">ANIMAL CELL</h3> 
<p>Shows toxins stored outside of the cells and on the cell membrane (which is made of fat/cholesterol)</p>	<p>Shows toxins stored inside the cells, which are often more damaging and detrimental to health.</p>

“People store their toxins intracellularly (inside cells): normally colored eyes; or extracellularly (on cellular walls): discolored eyes. Intracellular is more often worse than extracellular.”

This means a person with beautiful blue or amber eyes, which seem very clean, often indicates their toxins went intracellular, which is much more likely if you grew up with little body fat. The only exception would be if that person and their parents/grandparents never got vaccines, weren't exposed to much toxicity, ate raw animal foods mostly. In this unlikely scenario their clean blue or amber eyes would actually mean they are in excellent health.

Palm reading is very important and Aajonus did it as a mini-consult (5-10 mins long) at the end of some workshops and Q&A sessions, as well as reading the palms during iridology consults. Iridology is just much more detailed than palms and so takes longer and shows more details on the toxins and where they are stored.

4. Palmistry

How Palmistry is Done

Aajonus would tell most people to relax several times throughout the mini-consult because tensing the muscles (and as a result also tightening the tendons) in the hand could harden or misshape parts of the palm which would normally be softer, messing up the reading. Aajonus would extend the fingers of the person himself so they weren't using their own muscles

The mini-consults involved a combination of looking at the palms to see colouration as well as feeling the palms for their textures. Aajonus seemed a little psychic in some mini consults and ventured a little into traditional palmistry such as the examples below, so it is fair to say it probably takes someone with a strong intuition to do a full palm reading.

“A: Now you have that same artistic quality that she did, and you're going to have a tendency to be very critical. So it's for your creative mind. You get very bored. The two of you have similarities there, but I really couldn't read it from your hand because of the buckle finger, because it shows up in that finger. And it's your very creative mind. Be creative. I don't care if it's writing. I don't care what it is. I can't tell what it is that you're good and artistic at, but it could be movement. So get into a movement class, a dance class, or whatever it is, and let that diversification be your joy. Don't expect people to entertain you.”

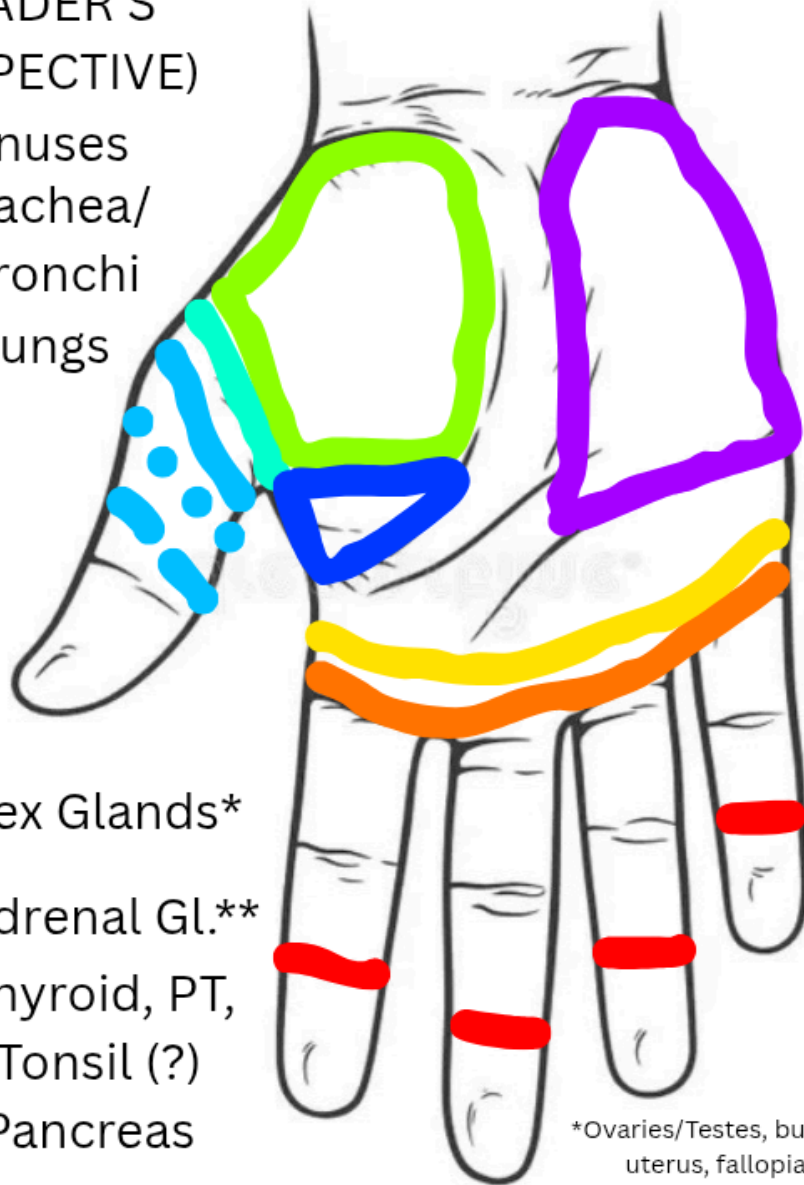
“And you're also very self-critical. You're very psychic. You should be a psychic. Be a healer. I mean, if you just get all your physical together, you've got one of the best relationship lines I've ever seen. You could be a matchmaker. You could be a marriage counselor. You could be all those things, and a good one. But you have to be happy in yourself first, and relaxed and calm.”

However, Aajonus repeated that it is not a psychic reading, and is only physiological.

“A: What I do is a short mini consult with the palms, and it's not [unintelligible]. It's not a psychic thing. It's like the Chinese patterns, colorations of mouths on the hands.”

RIGHT PALM
(READER'S
PERSPECTIVE)

- Sinuses
- Trachea/
Bronchi
- Lungs



- Sex Glands*
- Adrenal Gl.**
- Thyroid, PT,
Tonsil (?)
- Pancreas
- Digestive Area (?)

*Ovaries/Testes, but also prostate, uterus, fallopian tubes (?)

**The crease of the thumb

RED BLOOD CELLS are analysed by looking at the richness/saturation of the red splotches of the palm. The richer the red colour, the more abundant the body is in red blood cells. A higher amount of white splotches in the palm indicates

poor red blood cells even if they are abundant in quantity, and that they are not carrying oxygen well.

WHITE BLOOD CELLS are analysed by looking at the amount of white splotches in the palms. The more white splotches, the more white blood cell dominant a person is.

VERY COLD HANDS is indicative of severe mineral deficiency. That person needs to eat snacks of cheese and honey several times a day.

BACTERIAL LEVELS in different parts of the body can be seen. Perhaps this is a direct observation OR it's inferring from other observations.

LYMPHATIC CONGESTION is also shown by white splotches and the severity of the white splotches indicates severity of congestion. Pineapple and coconut cream are important for people with lots of lymphatic congestion.

LYMPHATIC WASTE (LESS ACCURATELY DESCRIBED AS SKIN CONGESTION) is not explicitly described in the palm, but Aajonus clearly did something to analyse skin congestion in the consult below. Watermelon is good for perspiration so perhaps him recommending melons to people was to do with skin congestion.

“This white splotching that you have, that's lymphatic congestion. It's not severe. More of the lymphatic waste is what you have. You see this, how much I can get in there? It should only be, see you're just so thick under there. I should only get a quarter and I'm almost getting two thirds, two eighths, I mean three eighths of an inch of toxicity. So you need the short baths more than the long baths. You need the 30, 35 minute baths every day to melt that stuff out of the system. Out of your connective tissue.”

”Remember, the *lymphatic waste* is that that's in the connective tissue being dumped under the skin and then the connective tissue to be perspired. *Lymphatic congestion* is when your lymphatic system is jammed. The glands and the nodes and the arteries going to and the veins, passages going to those lymph glands and nodes.”

SPECIFIC TOXINS SEEN IN PALMISTRY

TOXIC BILE IN THE BODY is seen by yellow discolourations of the palm. Discolourations are seemingly extremely subtle in the palm and many people probably won't be able to see this - I doubt if I can. Also consider palmistry, even the non-touching analyses, are best done in person and not digitally.

METALS includes a range of substances. Some specific ones I found in mini-consults are: tin, aluminium, iron, silver, mercury. Metals all seem to be variations of grey. Light grey, dark grey, silver-lavendar.

SMOKE TARS can be seen in the palms, and logically should be most concentrated in the respiratory areas. An extremely small number of people can turn the smoke tars into fats to use in the body, meaning a very tiny number of smokers will show little signs of smoke tars, except maybe in a small part of the body. In people who actually smoked the tars are concentrated in certain areas like the lungs and kidneys, but in secondhand smokers (people who were around smokers a lot), the tars are “patched” all over their system.

INDUSTRIAL SOLVENTS includes things like hexane, kerosene, petroleum derivatives, household cleaning products and potentially essential oils. Aajonus mentions a woman who reduced the green in her hands - green in the irises can indicate industrial solvents so perhaps this is the same (?).

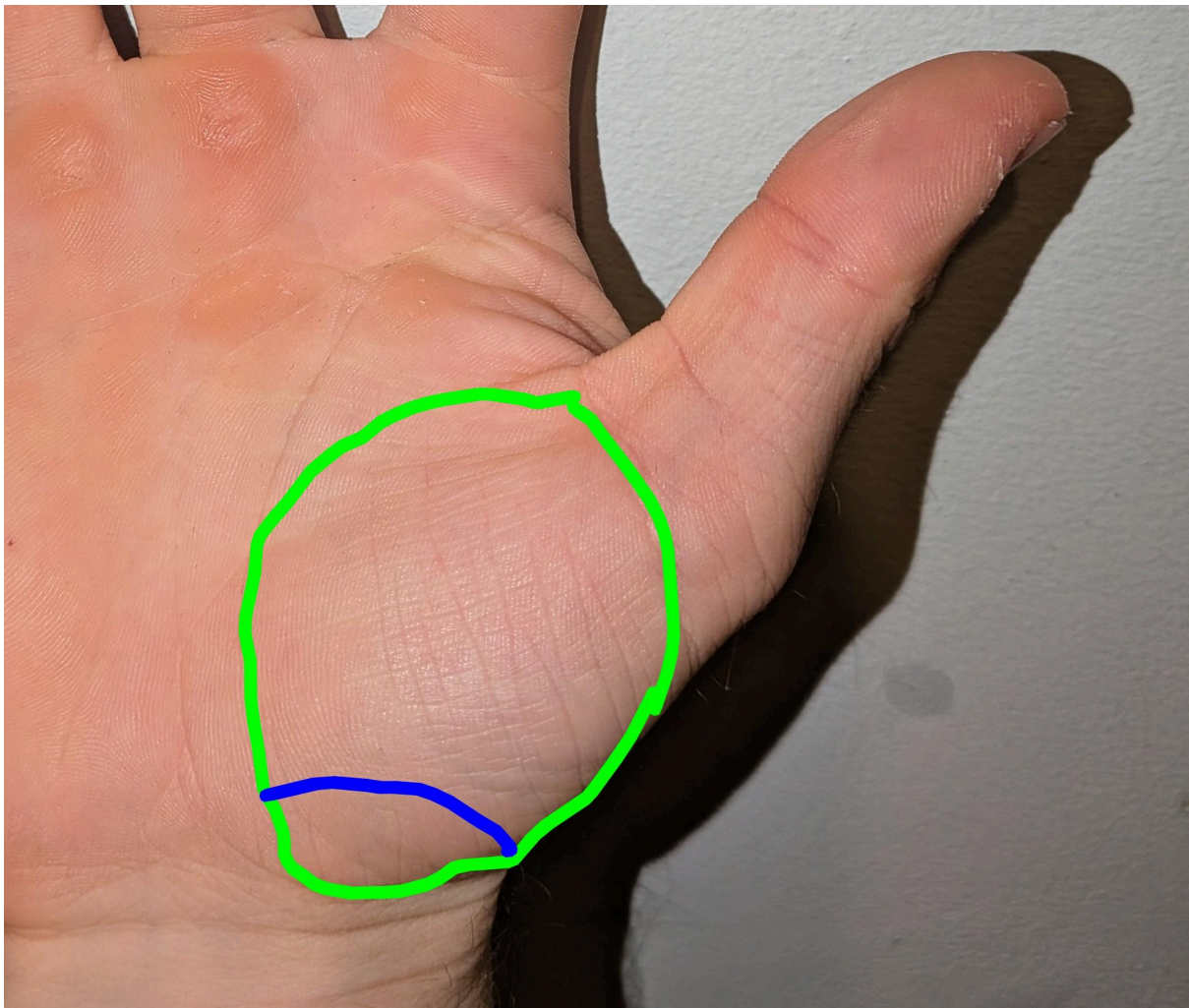
AREA SPECIFIC POINTERS

THE FOLLOWING APPLIES TO ALL AREAS UNLESS STATED OTHERWISE:

1. **FLAT/NO FAT PADS/WRINKLED SKIN** = LOWER LIFE
 2. **ROUND/GOOD FAT PADS/GOOD SKIN** = BETTER LIFE
- **OVERLY RED** = Swollen
 - **OVERLY WHITE** = Drying, Lymphatic Congestion (?)
 - **PUFFY** = Edemic (Edema - “Waterlogged”)


THE NAILS can show mineral detoxifications (or possibly mineral deficiency?) by going ridged. For Aajonus, he had periods of ridged nails paired with greying hair when detoxing minerals as he saw in his irises.

THE GONADS (TESTES/OVARIES) are in the fleshy mound at the base of the thumb. If this mound is very full and round (without the influence of exercise) it means that person has (over) active gonads. The prostate is closer to the wrist in this area. If there is a large bone in the prostate area, there is a tendency towards prostate issues. The fallopian tubes are somewhere distinct here but not specified. Below, the gonad is shown in the green circle with the prostate highly likely to be in the blue arc. With the prostate and uterus being interchangeable in iridology, I assume it is in the palm too.




THE ADRENAL GLANDS are displayed by the crease of the thumb, though it's slightly unclear whether it means the red or green dots below. Either way, the deeper this crease, the more overactive the adrenal gland (of that side) is.

Some people may have a deep crease from previously overactive adrenals but now have adrenal exhaustion if the area is also flat and lifeless. A shallow crease means lethargy/exhaustion and/or inactive adrenals.



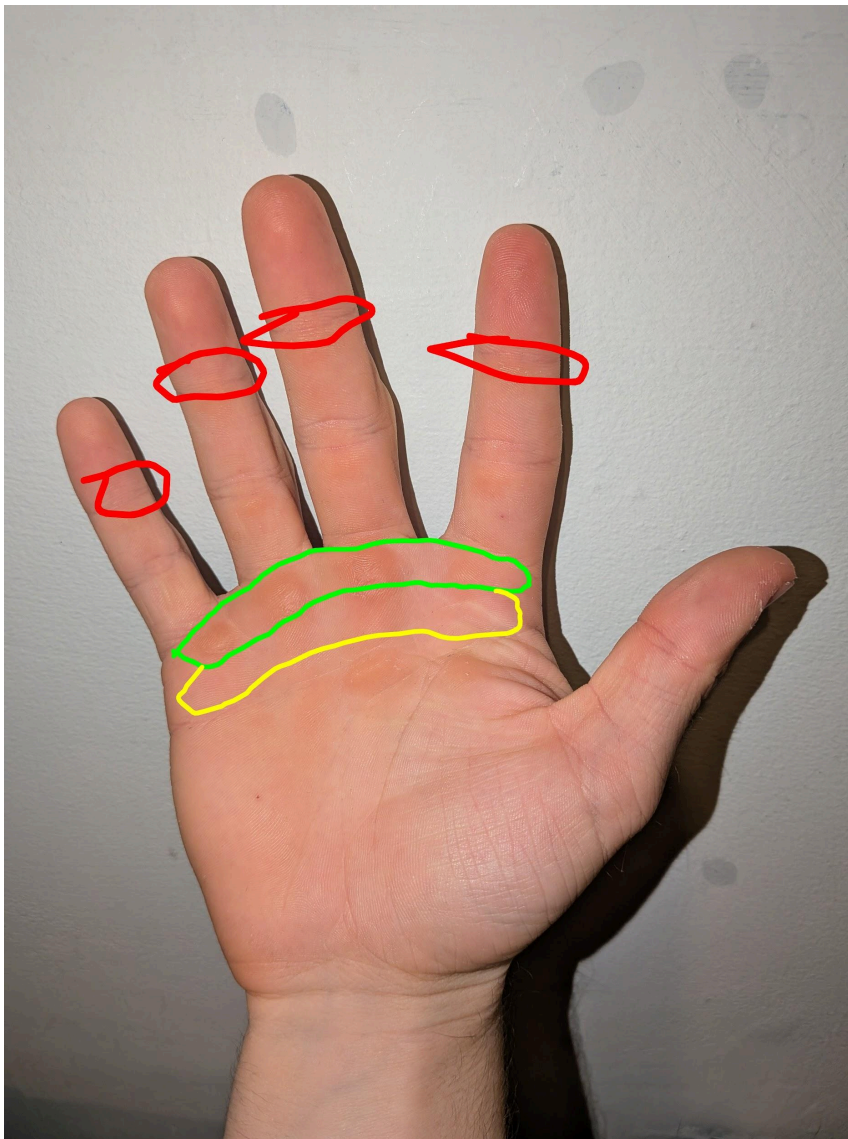
THE PANCREAS is shown just above the ball of the thumb in the fatty place. I interpret that as shown below. If it is red it is swollen, if it is puffy it is edemic (waterlogged). In either circumstance, it is deemed overactive, leading to hypoglycemia. If it looks like a chickens/turkeys cowl, all folded skin and no fat pads, it is more dead or inactive. I never used to get results searching for chicken cowl, but found this knitting product called by the same name. Alternatively, he means the wattle?



THE THYROID, PARATHYROID, AND TONSILS seem to be in the thumb. This is common in many palm reflexology charts, which Aajonus mentioned whilst teaching palmistry that a reflexology chart the students had with them was mostly accurate. All charts I have found misplaced the gonads

but show the thyroid, at least, in the thumb above the first joint. I cannot say how far up the thumb each of these glands are, but they are likely there.

THE RESPIRATORY SYSTEM (SINUSES, TRACHEA/BRONCHI/BRONCHIALS, AND LUNGS) are shown in the fingers and the top of the palm. From what I have read, the lungs sit just below the airway and the sinuses are in the last joint of the fingers. If the lung area is swollen, it could indicate infection (cold/flu) or allergies. If the lung area is white+swollen, it could indicate emphysema and poor circulation.



THE LIVER is shown in the right hand only, and is somewhere along the outer edge of the palm. Extract below:

“Aajonus: It’s in the right hand. The liver is in the right hand. You see how it is kind of hollow and sunken here? You see where it drops down this side? It’s more smooth. It goes on a slop. This actually drops.

— Yes. I see that. In other words, this slope here.

Aajonus: Yes. That’s normal, but a drop here shows not a very healthy liver. It’s not infected and it’s not swollen, so it’s not cleaning out right now.

— Infected would be white.

Aajonus: No, infected would be red. On here it’s red. In the eye area it’s white. The palm it’s red. So you said it’s not infected, and it’s not... what was the other thing? It’s not edemic because it’s not swollen. Depressed. It’s low. It’s a very underactive liver.”

[insert image here]

THE JOINTS are not actually a part of palmistry but Aajonus would look at how dry the wrist skin was to determine how lubricated the joints were. His reasoning was that the wrist is the most used joint and is most lubricated of all the joints, so if it is fat deficient (dry), the other joints likely are too. This can be indicative of arthritis, rheumatism, as well as lupus. The wrist skin can indicate candida if it’s dry and inflamed and splotchy.

**OTHER BODY PARTS NOT MENTIONED YET, BUT SEEN IN
MINI-CONSULTS ON AAJONUS.NET**

BRAIN

EARS

SPINAL CORD/BACK

INTESTINES

STOMACH

“SHOULDER BLADE DOWN TO THE WAIST”

KIDNEYS

LYMPHATIC SYSTEM

GALL BLADDER

THYMUS
HEART
LEGS